


THE IMMEDIACY CONCEPT

Treatment Planning
from Analog to Digital

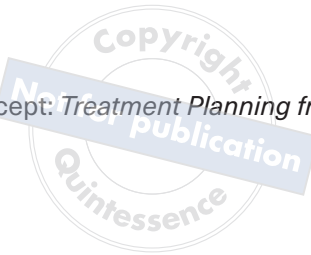Edited by

Edmond Bedrossian, DDS
E. Armand Bedrossian, DDS, MSD
Lawrence E. Brecht, DDS

with foreword by Daniel Buser, DDS, Dr med dent



The Immediacy Concept: *Treatment Planning from Analog to Digital*





One book, one tree: In support of reforestation worldwide and to address the climate crisis, for every book sold Quintessence Publishing will plant a tree (<https://onetreepanted.org/>).

Library of Congress Cataloging-in-Publication Data

Names: Bedrossian, Edmond, editor. | Bedrossian, E. Armand (Edmond Armand), editor. | Brecht, Lawrence, editor.

Title: The immediacy concept : treatment planning from analog to digital / edited by Edmond Bedrossian, E. Armand Bedrossian, Lawrence Brecht.

Description: Batavia, IL : Quintessence Publishing, Co, Inc, [2022] | Includes bibliographical references and index. | Summary: "Clinical manual for immediate implant treatment planning in the digital age, including the fundamentals of analog treatment planning that clinicians must master before moving to the digital realm"-- Provided by publisher.

Identifiers: LCCN 2021046221 (print) | LCCN 2021046222 (ebook) | ISBN 9781647240424 (hardcover) | ISBN 9781647241193 (ebook)

Subjects: MESH: Dental Implantation | Dental Implants | Digital Technology | Osseointegration | Case Reports

Classification: LCC RK667.I45 (print) | LCC RK667.I45 (ebook) | NLM WU 640 | DDC 617.6/93--dc23

LC record available at <https://lccn.loc.gov/2021046221>

LC ebook record available at <https://lccn.loc.gov/2021046222>

A CIP record for this book is available from the British Library.

ISBN: 978-1-64724-042-4



© 2022 Quintessence Publishing Co, Inc

Quintessence Publishing Co, Inc
411 N Raddant Road
Batavia, IL 60510
www.quintpub.com

5 4 3 2 1

All rights reserved. This book or any part thereof may not be reproduced, stored in a retrieval system, or transmitted in any form or by any means, electronic, mechanical, photocopying, or otherwise, without prior written permission of the publisher.

Editor: Marieke Z. Swerski
Design: Sue Zubek
Production: Angelina Schmelter

Printed in Croatia

THE IMMEDIACY CONCEPT

Treatment Planning from
Analog to Digital

Edited by

Edmond Bedrossian, DDS

Professor
Department of Oral & Maxillofacial Surgery
Dugoni School of Dentistry
University of the Pacific

Private Practice
San Francisco, California

Lawrence E. Brecht, DDS

Clinical Associate Professor
Director of Maxillofacial Prosthetics
New York University College of Dentistry

Director of Maxillofacial Prosthetics
Northwell Health

Private Practice Limited to Prosthodontics
and Maxillofacial Prosthetics
New York, New York

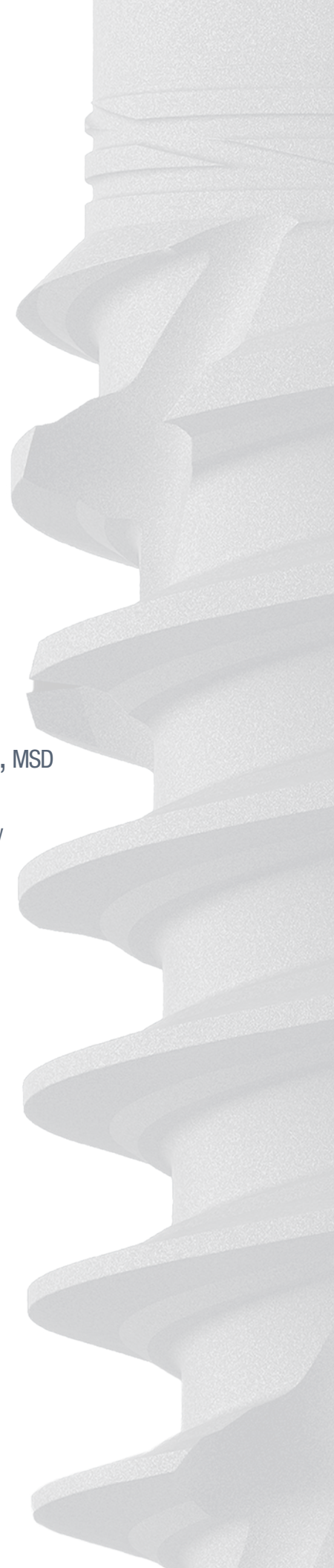
E. Armand Bedrossian, DDS, MSD

Affiliate Associate Professor
Graduate Prosthodontics Department
University of Washington School of Dentistry
Seattle, Washington

Private Practice
San Francisco, California

 **QUINTESSENCE PUBLISHING**

Berlin | Chicago | Tokyo
Barcelona | London | Milan | Mexico City | Moscow | Paris | Prague | Seoul | Warsaw
Beijing | Istanbul | Sao Paulo | Zagreb



Contents

Copyright
Not for publication
Quintessen

Foreword vi

Preface vii

Acknowledgments viii

Contributors ix

SECTION I **The Immediacy** **Concept**

1. Osseointegration Demystified 3

Peter Schupbach, Roland Glauser

2. Biologic Principles and the Immediacy Concept 19

Tara Aghaloo, Danny Hadaya, Delaney Islip

3. Implant Design for the Immediacy Concept 29

Edmond Bedrossian, Eirik Aasland Salvesen

4. Biomechanical Principles for Immediate Loading 39

Edmond Bedrossian

5. The Tissue-Level Implant 51

Edmond Bedrossian, Edgard El Char, Benjamin E. Pippenger, Eik Schiegnitz

SECTION II **The Digital** **Workflow**

6. Digital Workflow and the Immediacy Concept 69

Sonia Leziy, Brahm Miller

7. Digital Workflow Step by Step 95

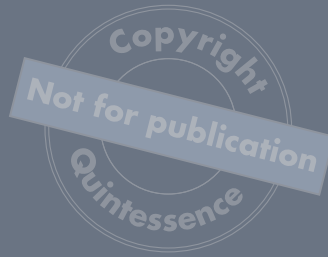E. Armand Bedrossian, Edmond Bedrossian

8. Complete Digital Workflow for Full-Arch Rehabilitation 121

Panos Papaspyridakos

9. Analog to Digital Workflow in Immediacy 133

Edmond Bedrossian, E. Armand Bedrossian



SECTION III
Treating Fully
Edentulous Arches

- 10. Loading Protocols for Full-Arch Rehabilitation 153
Waldemar Polido, Dean Morton, Wei-Shao Lin
- 11. Systematic Treatment Planning Protocol for the Maxilla 165
Edmond Bedrossian
- 12. The Tilted Implant Concept in the Maxilla 179
Edmond Bedrossian
- 13. Systematic Treatment Planning Protocol for the Mandible 195
Edmond Bedrossian, E. Armand Bedrossian

SECTION IV
Prosthetics for Full-
Arch Rehabilitation

- 14. Chairside Analog Conversion for a Fixed Provisional Prosthesis 217
Lawrence E. Brecht
- 15. Workflow and Material Choice for the Full-Arch Prosthesis 227
E. Armand Bedrossian
- 16. Managing Structural Complications of Full-Arch Restorations 247
Ricardo Mitrani, E. Armand Bedrossian, Jack Goldberg

SECTION V
Zygomatic Implants

- 17. Biomechanical Principles for Zygomatic Implants 265
Edmond Bedrossian
- 18. New Zygomatic Implant Design 287
Edmond Bedrossian, Sepehr Zarrine
- 19. Prevention and Management of Zygomatic Implant
Complications 297
Edmond Bedrossian

SECTION VI
Case Presentations

- 20. Case Presentations 317
Edmond Bedrossian, E. Armand Bedrossian

Index 391

Foreword

In the past 50 years, modern implant dentistry—based on the concept of osseointegration—has made tremendous and constant progress to the benefit of patients. Osseointegration was first described by the two research groups of Prof P-I Brånemark from the University of Gothenburg and Prof André Schroeder from the University of Bern. In the 1980s and 1990s, the basic surgical principles were defined, the clinical indications expanded from fully edentulous to partially edentulous patients, the submerged versus nonsubmerged healing modalities were examined, and new microrough implant surfaces were tested, which initiated a paradigm shift in the dental implant market.

Since the millennium change, we have been in a phase of routine application of dental implants. In the past 20 years, many efforts have been made to improve the attractiveness of implant therapy for patients by reducing the surgical invasiveness, pain and morbidity, and healing and treatment periods required. Various placement protocols with immediate, early, and late implant placement postextraction were defined at an ITI Consensus Conference in 2003. In addition, the different loading protocols with immediate, early, and conventional loading and restoration were defined 5 years later.

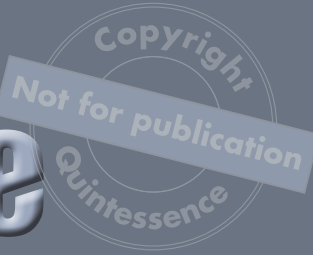The present textbook is edited by Dr Edmond Bedrossian, a gifted oral and maxillofacial surgeon and very experienced implant specialist. He was able to invite additional talented authors for contributions to the book, resulting in an excellent and very comprehensive textbook on the concept of immediacy. The first two chapters present the biologic basis of this concept, followed by relevant implant design aspects and biomechanical principles in chapters 3 and 4. Chapter 5 discusses the concept of nonsubmerged tissue-level implants, including the latest development with the TLX implant (Straumann). Chapters 6 to 9 then present the latest developments of the digital workflow in various clinical situations, which has had a tremendous positive impact for these implant treatments. The second half of the book deals with the treatment of fully edentulous patients, in particular the edentulous maxilla, where the immediate loading protocol is a tremendous service for patients for obvious reasons. The book then concludes with case presentations on all clinical situations described throughout to showcase everything that has been learned and how it can be applied.

The clinical chapters clearly show not only the great progress made with these treatment modalities, but also that these treatments are challenging for the clinician and complex in nature. Therefore, these procedures should only be carried out by skilled and experienced implant surgeons. Besides that, case selection based on well-defined selection criteria is very important to select the most appropriate treatment option in a given situation.

In conclusion, this is an excellent, clinically oriented textbook about the concept of immediacy in implant dentistry, and the reader will highly profit from the content. I congratulate Dr Edmond Bedrossian and the other authors. This book can be highly recommended to colleagues with an interest in this topic.

Daniel Buser, DMD, Dr med dent
Prof Emeritus, University of Bern

Preface



The emphasis of this book is that the preservation of alveolar hard and soft tissues is more predictable using the immediacy concept than is the reconstruction of the hard and soft tissues using the traditional delayed approach. Implant treatment is the most physiologic treatment offered to patients missing a single tooth, several teeth, and even their entire dentition. Internal loading of the alveolar bone with an implant-supported prosthesis maintains the alveolar bone volume after loss of teeth.

“Preservation is more predictable than reconstruction.”

Treatment of patients with missing teeth has evolved over the past three decades from two-stage delayed loading of implants placed in healed extraction sites to immediate implant placement with immediate provisional restoration placement at the time the teeth are removed. On the other hand, the rehabilitations of the terminal dentition patient and the existing fully edentulous patient have also evolved from delayed placement and delayed loading to immediate placement, which can be performed both in the maxilla and the mandible. What was the motivation for this dramatic change?

- Improved patient comfort and satisfaction
- Shortened treatment time
- Greater treatment acceptance

The vast body of published literature on this subject has allowed for many systematic reviews that clearly support immediate implant placement, fabrication of immediate provisionals, and immediate loading in appropriate clinical settings. Even in extreme cases of alveolar resorption, immediate implant placement with the use of tilted and/or zygomatic implants for the rehabilitation of the edentulous maxilla with a fixed prosthesis has also demonstrated success rates of over 97%. These published success rates are consistent with the 97% to 98% success rate expected with the traditional two-stage delayed loading protocols.

This book presents up-to-date information from discussion of the fundamental (analog) prosthetic and surgical treatment planning protocols to the integration and use of available digital workflows that complement everyday clinical practice. I am confident that readers will appreciate the journey through this book. The authors of every chapter underscore the fundamental scientific facts essential for predictable treatment planning with the practical presentation of clinical protocols for positive short- and long-term outcomes. This patient-centric approach results in the most contemporary and up-to-date information for our colleagues and their patients in every single chapter. The first chapter begins with a comprehensive discussion of distance and contact osteogenesis. Later chapters present the implant micro and macro design features necessary for achieving immediacy. Fundamental analog surgical as well as prosthetic protocols are presented in subsequent chapters. The role of the digital workflow is comprehensively discussed, and its use for the treatment of missing single to fully edentulous cases is presented through the remaining chapters. The final chapters illustrate multiple case reports utilizing and executing the information learned in previous chapters.



Prof P-I Brånemark's sentiment stands true today as it did the day he stated it:

"No one should die with their teeth in a glass of water."

The chapters written by leaders in the field of implant dentistry intend to follow the simple but powerful objectives set by Prof Brånemark, which include interdisciplinary collaboration, simplification, and following science with well-established treatment planning and protocols. The messages from each of Prof Brånemark's objectives are as follows:

Interdisciplinary collaboration between the implant team, the restorative dentist, the surgeon, and the laboratory technician is critical in proper treatment planning, execution of plans, and the long-term maintenance of implant reconstructions. In cases of patients with congenital and/or acquired maxillofacial defects, collaboration with our medical colleagues is also vital.

Simplification refers to the comprehensive understanding of a subject or a procedure. In order to discuss a subject or to execute a procedure and have others respond by saying, "You make it look simple," the complete command of the subject or the procedure is necessary. Knowing the level of predictable outcomes by proper preoperative clinical evaluation and treatment planning leads to practical and predictable prognosis. Therefore, realistic appreciation of the difference between "optimal" and "adequate" treatment outcomes is critical.

Following science and having a comprehensive knowledge of well-established protocols are essential to prevent complications. Following these objectives will lead to treating our patients in the most predictable manner with predictable long-term prognoses. After all, the patient is paramount.

Enjoy the content of this textbook; I am confident that you will find the comprehensive and contemporary information as essential for your daily practice as I do in mine.

Acknowledgments

This textbook was made possible by collaboration between global leaders of implant dentistry, and this collaboration has been a privilege and the highlight of my career. Without their unselfish sharing of their years of experience and knowledge, this project would not have been possible. I am extremely thankful for Drs Larry Brecht and Armand Bedrossian, who have been invaluable as coeditors as well as contributors to various chapters in this book.

Dr Danny Buser, an icon in the field of dental implants and ITI, has graciously written the foreword for this textbook, further confirming that the authors have provided implant teams with the most current and contemporary scientific information to treat our patients in the best possible manner.

I would also like to thank Elizabeth Murdoch Titcomb of Iolite Biomedical Communications for the creative illustrations throughout this textbook, allowing comprehensive and clear communications of many anatomical and technical concepts.

I am humbled by the collaboration of so many of the globally renowned authors of this textbook and am confident that we have honored the objectives set forth by my mentor, friend, and the father of osseointegration, Prof P-I Brånemark.

Contributors

Tara Aghaloo, DDS, MD, PhD

Professor
Division of Diagnostic and Surgical Sciences
Section of Oral and Maxillofacial Surgery
UCLA School of Dentistry
Los Angeles, California

Edmond Bedrossian, DDS

Professor
Department of Oral & Maxillofacial Surgery
Dugoni School of Dentistry
University of the Pacific

Private Practice
San Francisco, California

E. Armand Bedrossian, DDS, MSD

Affiliate Associate Professor
Graduate Prosthodontics Department
University of Washington School of Dentistry
Seattle, Washington

Private Practice
San Francisco, California

Lawrence E. Brecht, DDS

Clinical Associate Professor
Director of Maxillofacial Prosthetics
New York University College of Dentistry

Director of Maxillofacial Prosthetics
Department of Oral and Maxillofacial Surgery/
Dental Medicine
Department of Otolaryngology
Northwell Health

Private Practice Limited to Prosthodontics
and Maxillofacial Prosthetics
New York, New York

Edgard El Chaar, DDS, MS

Director, Advanced Education Program
in Periodontics
New York University College of Dentistry
New York, New York

Jack Goldberg, DDS, MS

Private Practice
Mexico City, Mexico

Roland Glauser, DMD

Private Practice
Zürich, Switzerland

Danny Hadaya, DDS, PhD

Resident
Division of Diagnostic and Surgical Sciences
Section of Oral and Maxillofacial Surgery
UCLA School of Dentistry
Los Angeles, California

Delaney Islip, BS

Dental Student, Class of 2022
UCLA School of Dentistry
Los Angeles, California

Sonia Leziy, DDS, Dipl Perio

Private Practice
Nanaimo, British Columbia

Clinical Associate Professor
University of British Columbia
Vancouver, British Columbia
Canada

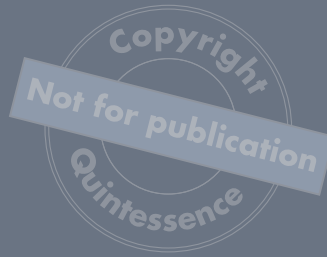Wei-Shao Lin, DDS, PhD

Associate Professor
Program Director, Advanced Education Program
Department of Prosthodontics
Co-Director, Center for Implant, Esthetic,
and Innovative Dentistry
Indiana University School of Dentistry
Indianapolis, Indiana

Brahm Miller, DDS, Dipl Pros

Private Practice
Nanaimo, British Columbia

Clinical Associate Professor
University of British Columbia
Vancouver, British Columbia
Canada



Ricardo Mitrani, DDS, MSD

Private Practice
Mexico City, Mexico

Affiliate Associate Professor
Department of Restorative Dentistry
University of Washington School of Dentistry
Seattle, Washington

Resident Faculty
Spear Education
Scottsdale, Arizona

Dean Morton, BDS, MS

Professor
Department of Prosthodontics
Director, Center for Implant, Esthetic,
and Innovative Dentistry
Indiana University School of Dentistry
Indianapolis, Indiana

Panos Papaspyridakos, DDS, MS, PhD

Associate Professor
Department of Prosthodontics
Tufts University School of Dental Medicine
Boston, Massachusetts

Benjamin E. Pippenger, PhD

Senior Scientist
Department of Periodontology
University of Bern
Bern, Switzerland

Waldemar Polido, DDS, MS, PhD

Clinical Professor
Department of Oral and Maxillofacial Surgery
Co-Director, Center for Implant, Esthetic,
and Innovative Dentistry
Indiana University School of Dentistry
Indianapolis, Indiana

Eirik Aasland Salvesen, DDS

Private Practice
Stavanger, Norway

Private Practice
Trondheim, Norway

Eik Schiegnitz, PD, Dr med dent, MSc

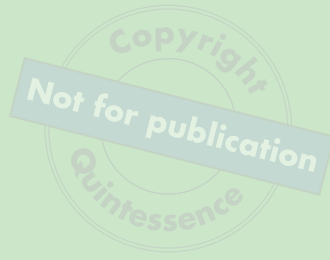Head of the Division of Implantology
Department of Oral and Maxillofacial Surgery
University Medical Center
Johannes Gutenberg-University
Mainz, Germany

Peter Schupbach, PD, ScD, PhD

Owner
Schupbach Histology and Imaging
Thawil, Switzerland

Sepehr Zarrine, DDS

Private Practice
Saint Dié, France



SECTION I

THE IMMEDIACY CONCEPT

Included topics:

- Osseointegration Demystified
- Biologic Principles and the Immediacy Concept
- Implant Design for the Immediacy Concept
- Biomechanical Principles for Immediate Loading
- The Tissue-Level Implant



Osseointegration Demystified

Peter Schupbach, PD, ScD, PhD
Roland Glauser, DMD

For decades now, dental implants have been successfully used to replace lost teeth, thereby restoring masticatory function, compromised esthetics, discomfort, and low self-confidence. Original surgical and restorative protocols focused on edentulous patients and included a strictly staged approach as the standard *modus operandi*. Over the decades, a myriad of developments has been introduced, including implant treatment of partial edentulism and aiming at simplification without jeopardizing predictability of dental implants. A main focus was on a reduction of the number of interventions, the invasiveness of the surgery, and the overall duration of the treatment. Moreover, changing patient demands have obviously stimulated a shortening of the entire treatment approach. Over the years, additional indications presenting with more advanced tissue conditions such as immediate implants have been included for treatments using dental implants.

Tooth-Supporting Tissues

The way our teeth are attached to the alveolar bone by the periodontal ligament (PDL) and protected by the marginal periodontium against foreign intruders is a masterpiece of tissue architecture and function. The cementum, PDL, alveolar bone, and gingiva form an evolutionary, structural, and functional unit called the *dental attachment apparatus*.¹ This unit serves several functions: it anchors the individual teeth to their bony alveoli and binds together one jaw's teeth into a dental arch. The PDL is a dense connective tissue composed of collagenous fibers and cells, blood vessels, and nerves. It is interposed in the space between the root surface of a tooth and the alveolar bone. Collagen fiber bundles called *Sharpey fibers* cross the space and are anchored in the root cementum at one end and in the alveolar bone at the other. Sharpey fibers are composed of hundreds of single collagen fibers. Every single fiber is deeply buried and anchored in the mineralized matrix of cementum and in the periosteum of the alveolar bone, respectively. On average, 28,000 collagen fiber bundles insert per 1 mm² area of cementum on a functioning tooth. The PDL works like a flexible suspension that allows resisting displacing forces and protects the teeth against an excessive occlusal load.

The primary functions of the gingiva around natural teeth are protection and stability; that is, to defend the interface between the teeth and the soft tissues against foreign invaders and to stabilize the position of the tooth in the alveolar bone. The structural framework that allows these tasks to be accomplished offers various spectacular details provided by evolution. Among them are how the gingiva and the underlying bone are protected by the highly specialized junctional epithelium and the way the collagen fibers of the connective tissue are attached to the tooth (Fig 1-1).

The junctional epithelium extends from the sulcular epithelium to the enamel/cementum junction and forms an epithelial, nonkeratinized sleeve around the tooth collar, thereby preserving the continuity of the epithelial coating of the oral cavity.² It is commonly accepted that the junctional epithelium is attached to enamel by the epithelial attachment apparatus, which comprises hemidesmosomes attached to the internal basal lamina. The unique structure and antibacterial peripheral defense mechanisms also allow for control of the lifelong constant microbiologic challenge. While the junctional epithelium forms the coronal part of the dentogingival junction, the apical portion is characterized by dentogingival collagenous fiber bundles extending in oblique angles into the root cementum. The resulting robust tissue attachment thereby supports the junctional epithelium and its rather fragile attachment mechanism by hemidesmosomes.

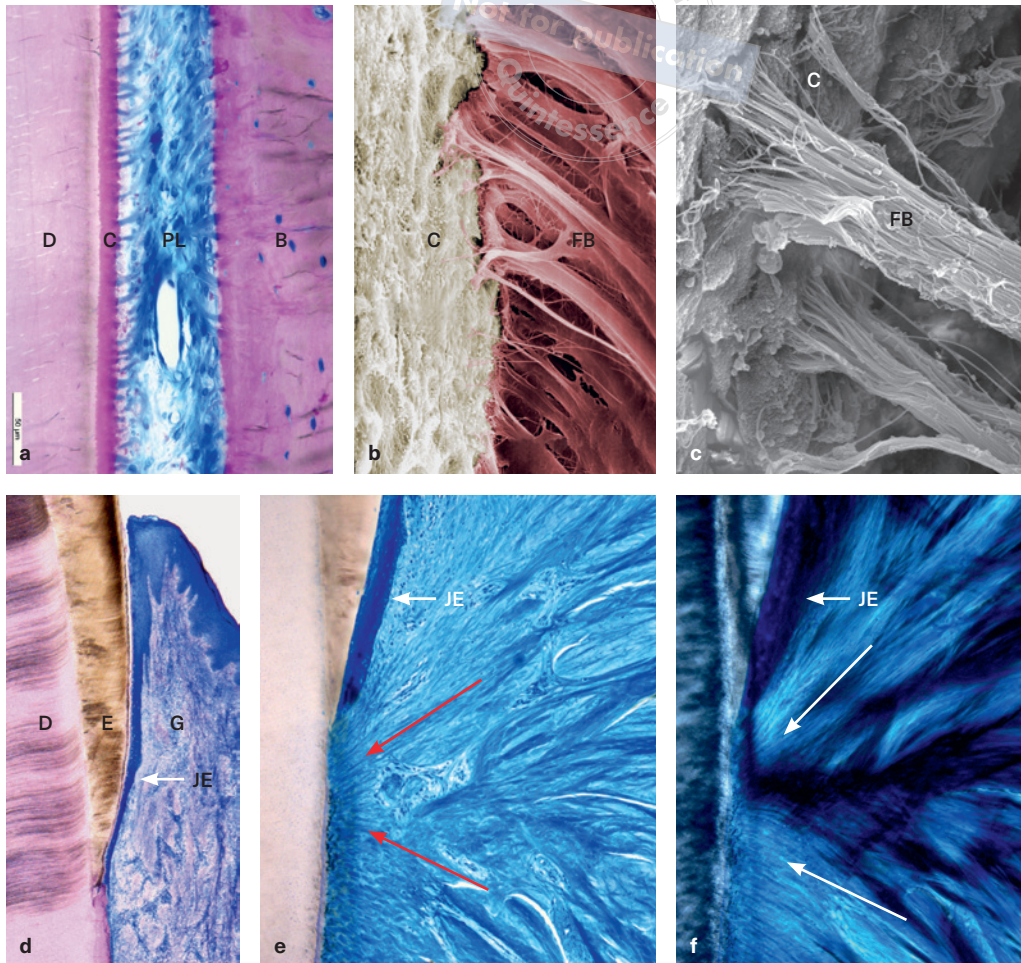


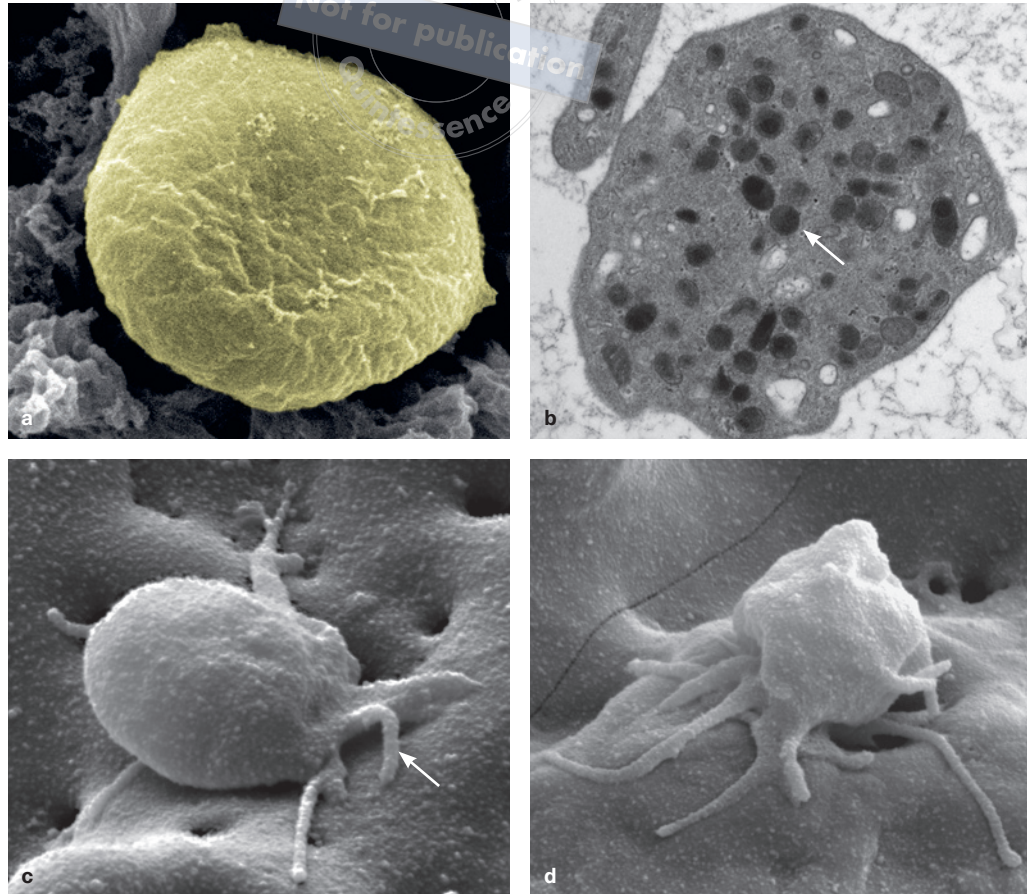
FIG 1-1 Dental attachment apparatus. (a) Longitudinal section through the periodontal ligament (PL). B: alveolar bone; D: dentin; C: cementum. (b and c) Sharpey collagen fiber bundles (FB) attached to root cementum (C). (d) Gingiva (G) attached to enamel (E); JE: junctional epithelium. (e) Functionally oriented collagen fibers (red arrows) viewed in transmitted light and (f) viewed in polarized light (white arrows).

Wound Healing Cascade and Bone Healing Mechanism

Both general wound healing and peri-implant wound healing of both soft and hard tissues are well-understood mechanisms.³⁻⁵ Several reviews have been published that focus on dental peri-implant healing.⁶⁻⁸ Placement of an implant into the alveolar bone is followed by a sequence of healing phases and bone formation, resulting in osseointegration. A temporal sequence of peri-implant wound healing is given in Fig 1-2. This sequence is based on a dog study, and the reader must consider that the healing in this model is five times faster than in humans.

Hemostasis represents the first phase of peri-implant healing around implants. Hemostasis is begun by blood platelets, which are the first cells that interact with the implant surface. Inactive platelets have a discoid shape and are the smallest of the many types of cells in circulating blood, averaging only 2.0 to 5.0 μm in diameter and 0.5 μm in thickness. Sections in the equatorial plane reveal that platelets contain granules filled with growth factors and enzymes, such as platelet-derived growth factor (PDGF) and transforming growth factor β (TGF- β), together with vasoactive factors such as serotonin and histamine. These factors play a crucial role in regulating the following wound-healing cascade.⁹ After leaving an injured blood vessel, the platelets are activated immediately by injured collagen fibers and tissues. Besides the latter, biomaterials placed in the body can activate platelets. It takes only 2 minutes to initiate the fibrin formation on titanium surfaces.¹⁰

FIG 1-2 Platelet activation. (a) Scanning electron micrograph (SEM) of an inactive platelet. (b) SEM view of a section through an inactive platelet. Note the presence of numerous granules (arrow) containing growth factors and enzymes. (c) SEM of an initial stage of platelet activation. Note the outgrowth of pseudopodia (arrow). (d) Activated platelet.



When activated, platelets change in shape to become more spherical, and pseudopods form on their surface (Fig 1-3). As a result, they assume a stellate shape with a considerably enlarged surface. Chemical reactions change the surface of the platelet to make it sticky. The platelets clump together to form aggregates. Such aggregates will plug small blood vessels in the periphery of the wound, and bleeding will be slowed and finally stopped. Clotting proteins form out of fibrinogen, long sticky strands called *fibrin*. Only 10 to 20 minutes after implant placement, a blood clot composed of blood cells, activated platelets, and fibrin strands is adherent to the implant surface. Simultaneously, the platelet envelope collapses, and the granules are released. These factors will regulate early wound healing by attracting the cells needed during the next phase of wound healing, the inflammatory phase.

Once bleeding is controlled, inflammatory cells are attracted and migrate to the wound area to promote the inflammatory phase (Fig 1-4). Initially, leukocytes are the most numerous cells, peaking at 48 hours following implant placement. The critical function of the leukocytes is the degradation of the fibrin clot as indicated by the *red arrows* in Fig 1-4d and clearance of invading bacteria and debris in the wound area. Macrophages rapidly follow neutrophils. Macrophages play multiple roles in wound healing. One of them is removing the leukocytes, thus paving the way for the resolution of the inflammation. They also attract stem cells and fibroblasts to the wound area and start angiogenesis. In this way, macrophages promote the transition to the now following proliferative phase.¹¹

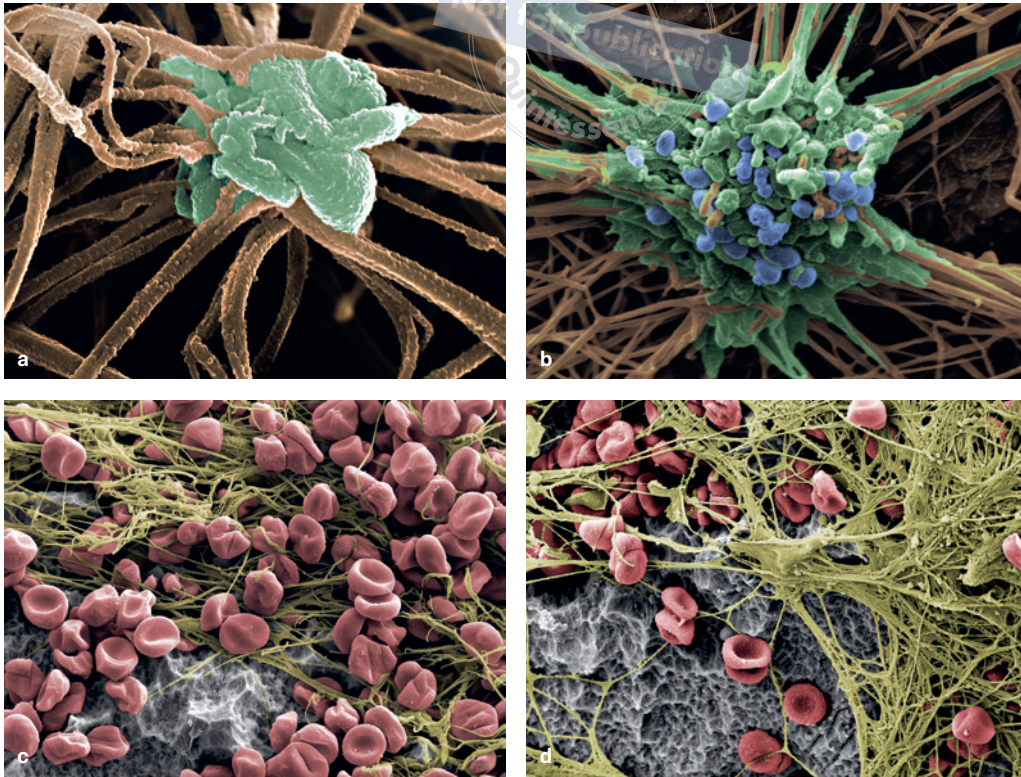


FIG 1-3 Hemostasis. (a) Colored SEM of a platelet (green) entrapped in the fibrin mesh (brown). (b) Colored SEM showing the release of granules. (c and d) SEM of the blood coagulum attached to an SLActive implant surface.

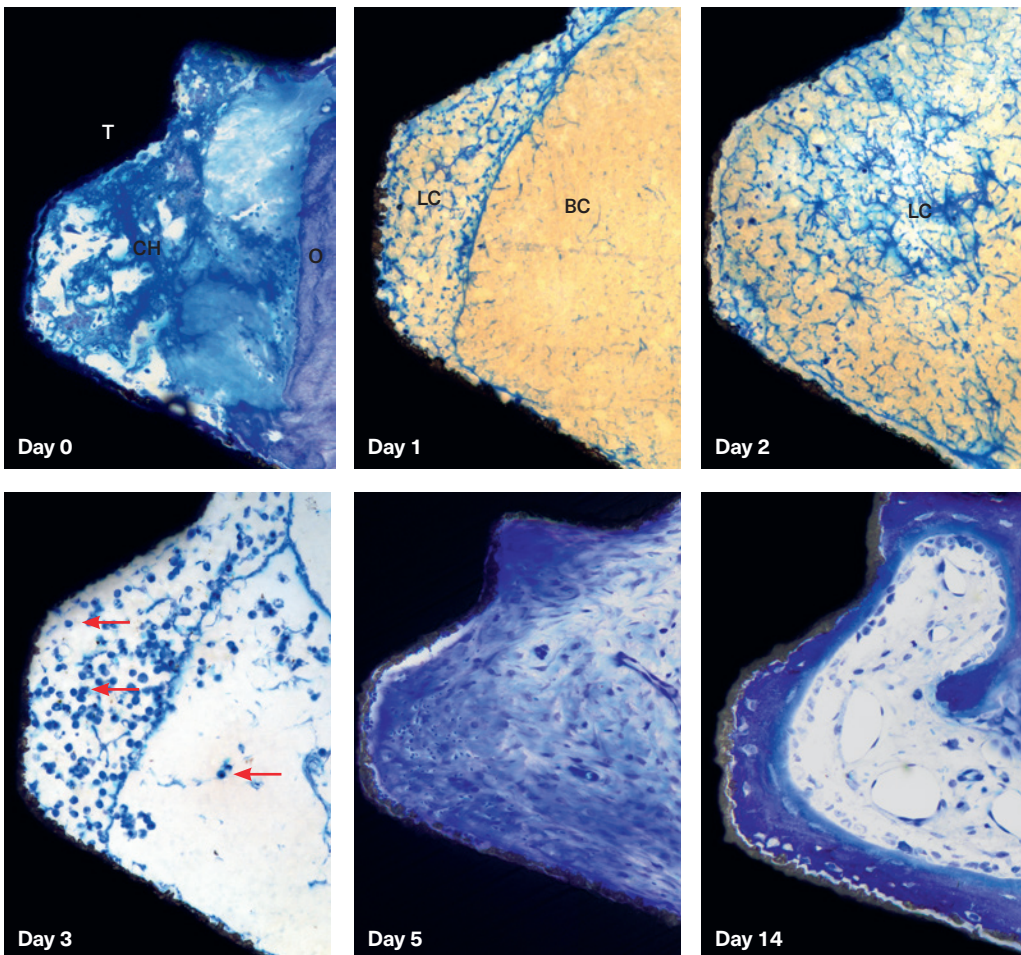


FIG 1-4 Temporal sequence of early wound healing in a dog model. Day 0: Border wall of the osteotomy (O) and bone debris between the threads (T). Day 1: A blood coagulum (BC), and partially and area of lysed coagulum (LC). Day 2: Advanced lysis of the coagulum. Day 3: Removal of the fibrin remnants removed by neutrophils (arrows). Day 5: Provisional matrix between the threads. Day 14: Initial bone formation by contact osteogenesis.

The proliferative phase (see Fig 1-4) is characterized by the replacement formation of granulation tissue, angiogenesis, collagen deposition, and wound contraction by myofibroblasts. In granulation tissue formation, fibroblast-like cells invade the wound and form a provisional extracellular matrix by secreting collagen and fibronectin. New capillaries are formed by vascular endothelial cells. They derive from endothelial cells of the original capillaries but also from the circulating endothelial progenitors.¹² Simultaneously, fibroblast-like mesenchymal cells differentiate into osteogenic cells and finally to osteoblasts. The latter will deposit a layer of collagen fibers, the so-called osteoid, which becomes mineralized, and by that, woven bone is formed. During this process, some osteoblasts will become entrapped in the osteoid layer and surrounded by the mineralized matrix and form the osteocytes in living bone.¹³

The Event of Osseointegration

The surgical preparation of an osteotomy into native or regenerated bone and subsequent implant insertion will lead to a sequence of healing steps at the tissue interface that results mostly in the event classified as osseointegration.¹⁴ We should notice that this implant-bone relationship is a very intimate one, but obviously it is an osseoadaptation rather than a real osseointegration. Nevertheless, the terminology of osseointegration has been established and has been used consistently for more than six decades.

One of the prerequisites for proper osseointegration is a stable implant anchorage and no relative movement (also described as *micromotion* or *micromovement*) to surrounding tissue (Fig 1-5). It is mandatory to understand the importance of implant stability over time and the sequence of bone healing, and likewise important to know that implant surfaces, implant designs, and surgical approaches influence the interactions between tissues, cells, and the dental implant.

Osseointegration refers to a direct structural and functional connection between ordered, living bone and the surface of a load-carrying implant.¹⁵ Therefore, an implant is considered as osseointegrated when there is no relative movement between the implant and the anchoring bone.

A direct bone-to-implant contact as observed histologically may be indicative of the lack of a local or systemic biologic response to that surface. It could be concluded that osseointegration is not the result of an advantageous biologic tissue response but rather the lack of a negative tissue response.¹⁶ Hence, with a successful osseointegration, a beneficial foreign-body reaction has been established.¹⁷

Different Patterns of Bone Healing Around Implants

Two completely different mechanisms of bone formation are present around dental implants: distance and contact osteogenesis.¹⁸ In distance osteogenesis (Fig 1-6a), osteogenic cells, such as pericytes, become differentiated to osteoblasts that secrete the collagen-containing matrix of bone in the provisional matrix. Eventually, the matrix becomes mineralized by hydroxyapatite (HA) crystals also deposited by osteoblasts.

Bone formation by distance osteogenesis always starts away from the implant at the osteotomy wall and involves an ordinary sequence of bone wound healing as present in the

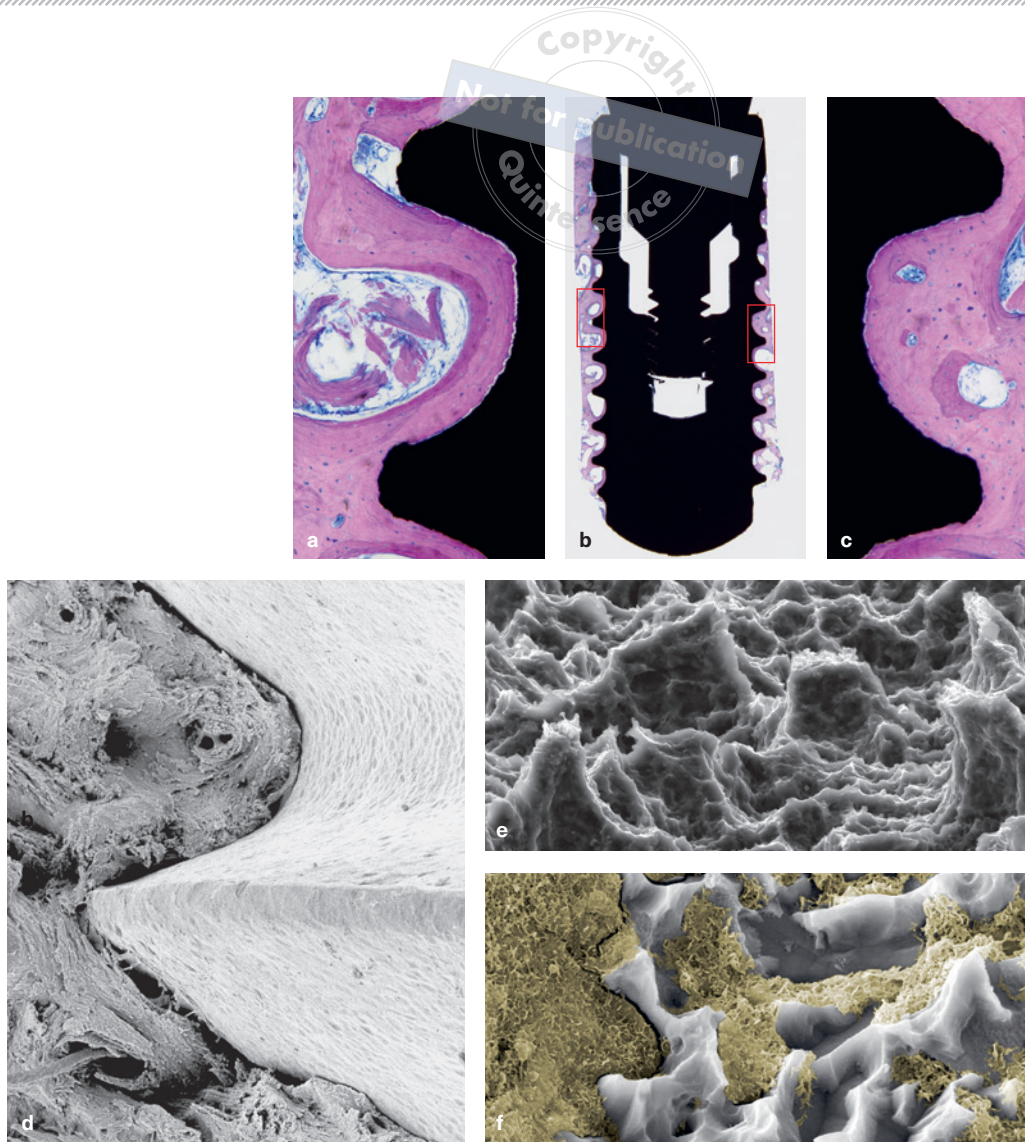


FIG 1-5 Final osseointegration. (a to c) Human histology of a Straumann Bone Level implant trephined out following 3 years in place. (d) SEM illustrating the intimate adaption of bone to an implant surface. (e) SEM view of an SLActive surface. (f) SEM view of bone anchorage in an SLActive surface.

tooth extraction socket or the bone marrow ablation site (see Fig 1-6a). The front of newly formed bone advances by distance osteogenesis radially to the implant surface. Only when newly formed bone reaches the implant surface does the implant's secondary stability, a biologic stabilization of the implant, take place.

Bone formation by contact osteogenesis (Figs 1-6b and 1-6c) needs contact points between local bone with the implant surface, either between the implant thread tips with dense bone or between the implant surface with bone trabecula of soft bone. Outgoing from these contact points, bone formation occurs directly on the implant surface and is spreading around the implant.¹⁹ In detail, osteoblasts deposit the collagen matrix directly on the surface, and the matrix becomes mineralized. By that, initially, a thin band of newly formed woven bone will be deposited directly on the surface, and along the surface, as continuously osteoblasts are streaming to the front of bone formation. Simultaneously, osteoblasts also line the layer of newly formed bone. By that, the thin band of newly formed immature woven bone gains in thickness by appositional bone growth.

FIG 1-6 Bone healing mechanisms. (a) Woven bone formation by distance osteogenesis outgoing from the osteotomy wall (W). The first newly formed woven bone trabeculae (T) already crossed the gap to the implant and reached its surface. (b) Woven bone formation by contact osteogenesis outgoing from contact points between local trabecular bone (*green rectangles*) and extending as a thin band toward the valley between the threads. (c) Contact osteogenesis. Osteoblasts deposit a layer of collagen fibers, called *osteoid*, which becomes mineralized, and by that, woven bone is formed.

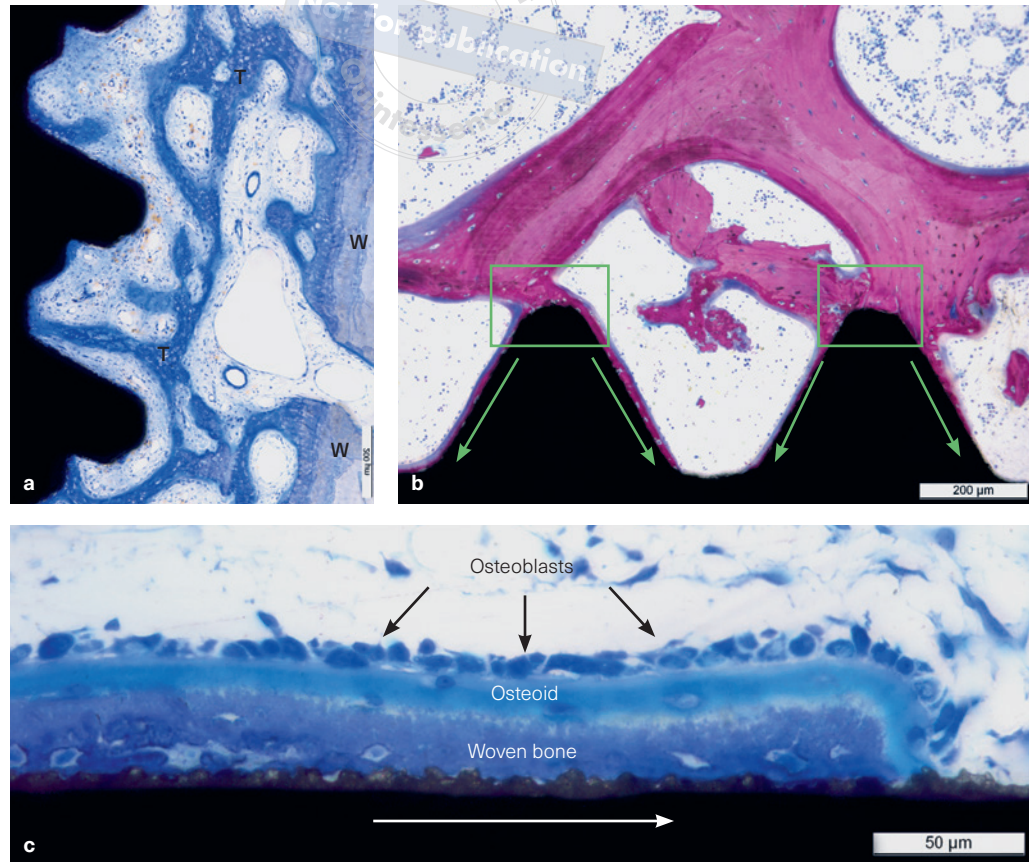
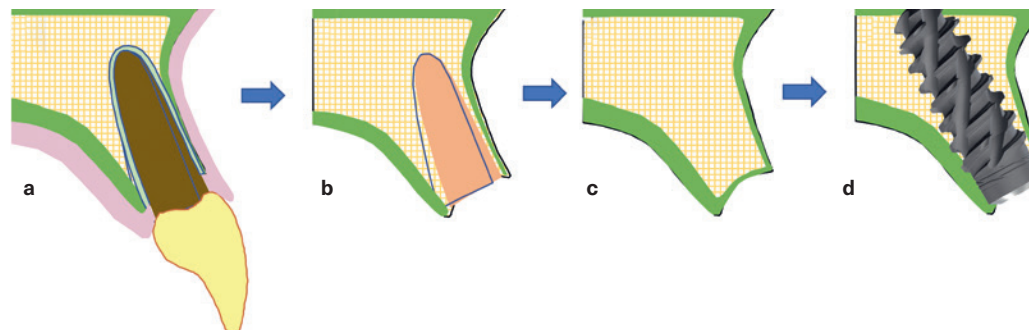


FIG 1-7 Bone conditions in a healed site in the incisor region. (a) Anatomy before tooth removal. (b) Socket configuration after tooth removal. (c) Bone contours following healing with cortical zones in *green*. (d) Bone-to-implant relation after implant placement.



Woven bone, formed by both distance and contact osteogenesis, is gradually remodeled and replaced during a time period of 1 to 3 months by lamellar bone containing bone marrow adipocytes, blood vessels, and collagen fibers. In many respects, this process is similar to the bone healing occurring at a fracture site.

Implants Placed in a Healed Site

When you are aiming for a stable implant anchorage during the early wound healing phase, there should be a well-balanced mix between (1) dense host bone areas (Fig 1-7; *green zone* with slower turnover) with primary implant contacts enabling high primary implant stability and (2) soft bone areas (with faster turnover) facilitating new bone formation.

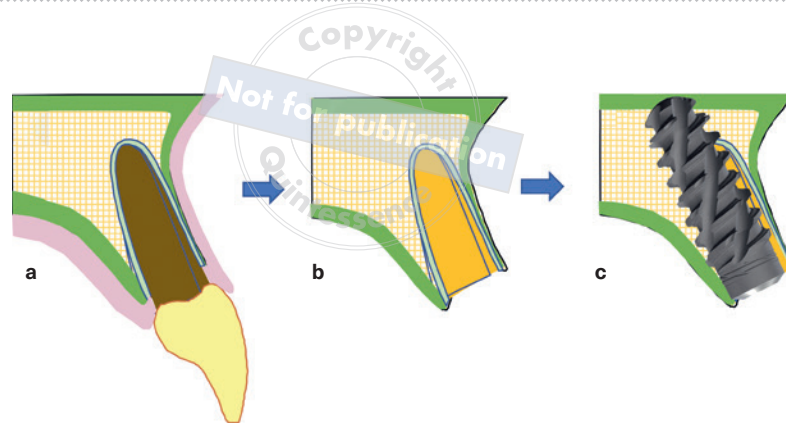


FIG 1-8 Bone conditions in an immediate site in the incisor region. (a) Anatomy before tooth removal. (b) Socket configuration after tooth removal. (c) Bone-to-implant relation after implant placement with cortical zones in green. Remaining socket (bone defect) in orange.

Immediate Implant Placement

Aside from surgical skills, there are three factors that primarily influence successful immediate implant placement and subsequent osseointegration:

1. Local bone quality and quantity
2. Number of primary bone-to-implant contacts established with implant placement
3. Speed of new bone formation at the bone-implant interface

Implants placed immediately following tooth removal are usually inserted toward the palatal or lingual aspect of the alveolar socket in order to engage sufficient local bone and to improve initial implant anchorage. In addition, working length during surgical site preparation also intends to reach periapical host bone (if anatomically possible) so that the implant can achieve even more stabilization.

Referring to an intact socket configuration, this insertion strategy creates two distinct peri-implant environments: (1) on the palatal and apical aspect, the implant is in direct contact with host bone (*green zone* in Fig 1-8), while (2) on the buccal and to some extent on the interproximal aspect, a gap exists between implant and socket wall (*orange zone* in Fig 1-8).

Hence, from a biologic point of view, it is important to understand different bone healing patterns when dealing with these unequal starting conditions (Figs 1-9 to 1-11). Moreover, it is important to understand that an implant surface is a nonvital counterpart that slows down revascularization in adjacent wound areas, but the surface may speed up bone healing with particular surface characteristics (eg, morphology, chemistry).

In general, when placing an implant into an extraction socket, a wider implant diameter would proportionally reduce remaining defect volume to the socket when compared with a narrower diameter. This simple geometric effect would favor selection of wider implants when dealing with extraction sockets. However, with regard to long-term peri-implant tissue stability, implant diameter selection has changed over the last few decades from rather wide diameter implants in the 1990s toward a more narrower neck diameter. Whereas in early years, a wider implant was intended to fill up more of the resulting socket defect, today, a slim neck portion leaves more space for hard and soft tissue formation and thereby allows for a reliable long-term marginal tissue maintenance.

FIG 1-9 Socket morphology in relation to implant geometry in the incisor region. (a) Alveolar cross section (orange) in CBCT diagnostics. (b) Cross section illustrated on maxillary skull model. Exemplary implant will be stabilized on palatal area (green) with remaining buccal defect area (orange). (c) Sagittal view in CBCT with implant and remaining defect morphology (orange).

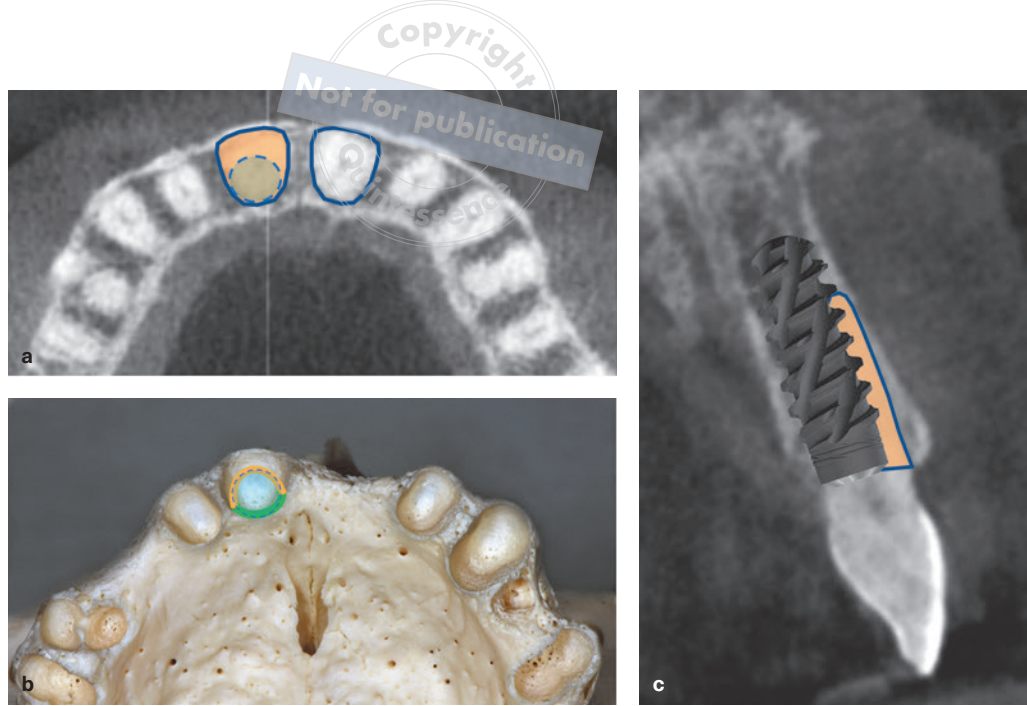


FIG 1-10 Bone conditions in an immediate site in the premolar region. (a) Anatomy before tooth removal. (b) Socket configuration after tooth removal. (c) Bone-to-implant relation after implant placement with cortical zones in green. Remaining socket (bone defect) in orange.

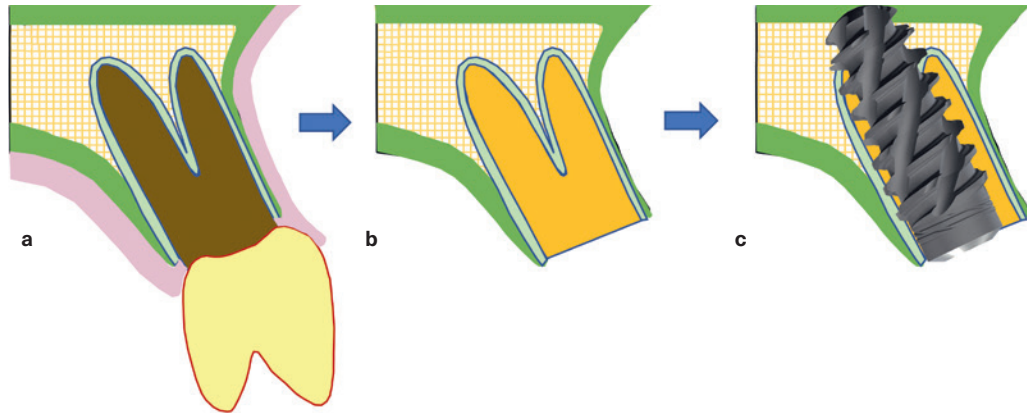
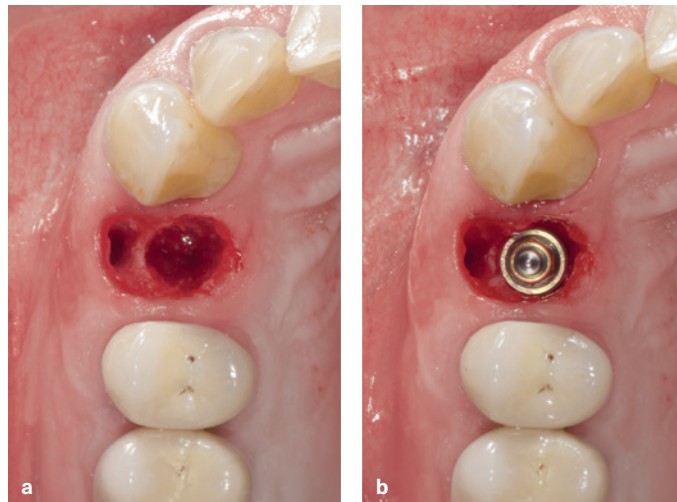


FIG 1-11 Bone conditions in an immediate site in the premolar region. (a) Socket configuration after tooth removal. (b) Bone-to-implant relation after implant placement with orientation to the palatal aspect. Remaining socket (bone defect) in buccal area.



Implant Macro Design and Surface: Impact on Early Bone Healing

The original Brånemark implant was a machined (turned) screw with a low surface roughness value of 0.5 μm . The fixtures were left undisturbed and unloaded for several months so as not to disturb the wound healing and not compromise osseointegration. Over the following 25 years, surface modifications have been a significant focus of implant dentistry. Numerous in vivo and in vitro studies have been identified with surface topography, chemistry, surface charge, and wettability to demonstrate the effect of surface modifications on osseointegration of titanium implants.^{20,21} Early studies with titanium-plasma-sprayed (TPS) and HA implants, both exhibiting a rough surface, have shown faster osseointegration than machined implant surfaces.²² This was confirmed later by a study using fluorochrome labeling of bone, suggesting that contact osteogenesis occurs at a rate that is 30% faster than distance osteogenesis.²³

In the 1990s, the group of modern implants as are used today started to show up. Among them are sandblasted, large-grit, acid-etched surfaces as SLA and SLActive (Straumann), grit-blasted and acid-etched surfaces as Friadent and Friadent Plus (Dentsply Sirona), titanium oxide blasted surfaces as Osseospeed (Dentsply Sirona), and anionic oxidized surfaces as TiUnite and TiUltra (Nobel Biocare), just to name a few. The common property of these implants is their surface roughness, with Sa values between 1.0 and 2.0 μm . Compared with machined surfaces, the group of moderately rough implants resulted in significantly higher bone-to-implant contact values and faster bone formation.^{24,25} Therefore, there is no doubt that a surface's roughness is the key to getting significantly more bone at earlier time points following implant placement.

All types of moderately rough implant surfaces as mentioned here are highly osteoconductive and allow for contact osteogenesis. The accelerated osseointegration allows the site to maintain the primary stability to achieve faster secondary stability than machined implants, thereby allowing for early or immediate loading of an implant.²⁶

Implant macro design not only secures initial fixation of the implant; smaller self-cutting design features also intend to generate bone debris (ie, small bone particles) along their insertion path. In particular, bone debris resulting from the surgical site preparation as well as that generated during implant insertion seem to be involved in trabecular bone formation during the first weeks by guiding and improving peri-implant osteogenesis as an osteoconductive biologic substrate. As a consequence, clinical practice recommends not flushing or aspirating the bone cavity before and during the implant insertion.²⁷ A moderately rough surface will further support the adherence of bone debris. In addition, the surface texture itself will generate additional smaller bone particles because of its abrasive effect during implant installation.²⁸ This abrasive effect results in a smear layer several microns thick composed of bone debris and blood covering the implant surface. This smear layer provides osteoinductive potential.²⁹⁻³¹

Implants designed with macroscopic self-cutting features at the apex or along the implant axis (eg, BLX implants, Straumann), are collecting larger bone particles in these areas during implant installation (Figs 1-12 and 1-13). As a basic principle, gaps between the osteotomy and the implant body have to be crossed via distance osteogenesis. This slower process will be accelerated as bone formation is guided along these osteoconductive bone particles toward the implant surface. As soon as the implant surface is reached, new bone is formed directly on and along the surface by contact osteogenesis (see Fig 1-13).

FIG 1-12 SEM illustrating abrasive effects. (a) Smear layer composed of blood cells and small bone particles. (b) Bone debris covering larger areas of the thread morphology.


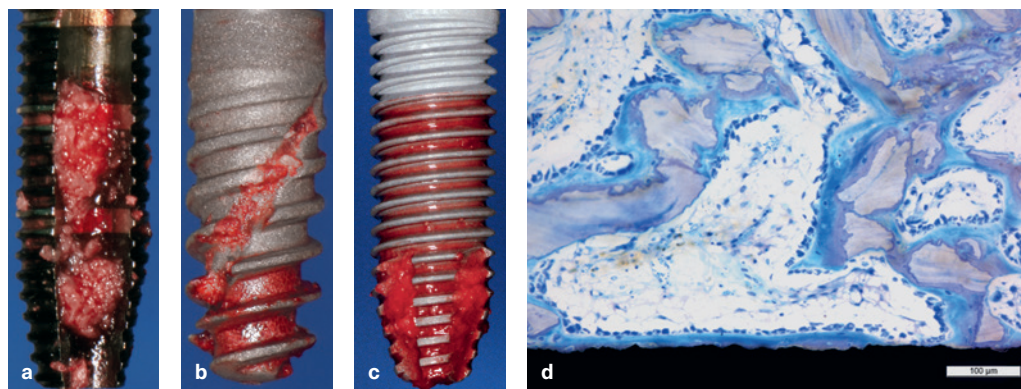


FIG 1-13 Implant macroscopic self-cutting features. (a) Screw tap collecting larger bone particles during implant bed preparation. (b) Spiral self-cutting features along implant axis are filled with bone particles during implant insertion (BLX implant design). (c) Apical cutting features are loaded with larger bone particles during installation (tapered implant with apical cutting design). (d) Bone formation is guided along the osteoconductive bone particles toward the implant surface. As soon as the implant surface is reached, new bone is formed directly on and along the surface by contact osteogenesis.

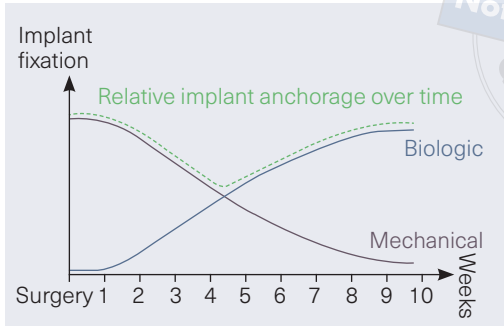


Changes in Implant Anchorage During the Early Healing Phase

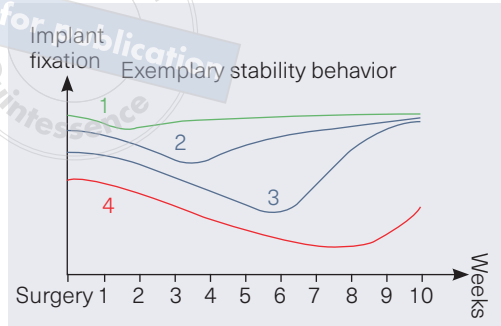
Biologic fixation differs from the primary (mechanical) stability that is obtained with the implant insertion. Biologic fixation of the implant involves early peri-implant bone formation that establishes a firm fixation of the implant^{32,33} (Fig 1-14). In humans, peri-implant bone formation begins as early as 10 to 14 days after implant placement.

Obviously, the more favorable the local hard tissue conditions, the higher the primary implant stability, and the better this initial anchorage can be maintained over time, the earlier the implant can be functionally loaded.³³ Therefore, in some conditions, implants can be loaded immediately following implant placement. On the other hand, the larger remaining peri-implant bone deficiencies and/or when dealing with poor bone quality as well as poor bone-to-implant contact area, the more immediate or early loading should be assessed more critically^{34,35} (Fig 1-15).

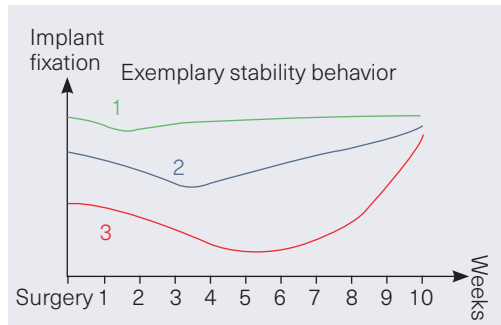
Initial implant stability (ie, primary stability) is influenced by the local bone quality and quantity, the selected site preparation technique, and the chosen implant macro geometry.³⁶ Taking bone quantity and quality as well as specific site drilling protocol for granted, initial implant stability will remarkably be controlled by implant geometry (Fig 1-16). Modern implant designs with obvious bone cutting and condensing features (eg, tapered body, progressive thread profile, self-cutting characteristics) will generate a significantly higher primary stability when compared with traditional implant designs (eg, parallel-walled implant body, low thread profile, no self-cutting properties).



Primary bone contacts enable mechanical fixation (press fit)
 Secondary bone contacts lead to biologic fixation (contact and distance osteogenesis)



- 1 Dense bone condition, long implants, and/or implant splinting
- 2 Mixed bone conditions and long/wide diameter implant
- 3 Mixed bone conditions and short/narrow diameter implant
- 4 Soft bone conditions, peri-implant bone defect, and/or short implant



- 1 Implant macro geometry enabling effective bone cutting and compression, eg, BLX
- 2 Implant macro geometry with reduced bone cutting and compression features, eg, BLT
- 3 Implant macro geometry with relative passive insertion handling, eg, Straumann Standard

◀ FIG 1-14 Changes in implant stability following surgery.

▶ FIG 1-15 Exemplary stability behavior of implants in different bone conditions over time. The larger the fraction of the implant surface without initial bone contact presents, the more time is needed until newly formed bone functionally supports the implant in these areas. Nonetheless, due to their morphologic configuration, some bone defects may allow for faster tissue regeneration (eg, intrabony defects) and would allow for an early loading approach.

FIG 1-16 Exemplary effect of implant macro design on initial and early implant stability.

Conclusions

Biologic conclusions

- In humans, peri-implant bone formation begins as early as 10 to 14 days after implant placement.
- Surface characteristics of dental implants play a key role in hard tissue integration. There is no doubt that the roughness of a surface is the key to getting significantly more bone at earlier time points following implant installation.
- Moderately rough implant surfaces present approximately 20% to 30% more surface area than smooth surfaces.
- The wettability of a surface influences the initial speed of healing (fibrin and cell adherence).
- Moderately rough implant surfaces reveal a higher osteoconductivity than smooth surfaces. An osteoconductive surface is a precondition for contact osteogenesis.
- Contact osteogenesis occurs at a rate 30% faster than distance osteogenesis.
- In healed sites, bone-to-implant contact is around 15% to 30% for the majority of all implants directly after implant insertion, regardless of the surface.
- Bone-to-implant contact is higher in dense bone conditions as compared with soft bone conditions, regardless of the surface.
- Bone-to-implant contact is around 50% to 70% for the majority of all implants with moderately rough surfaces when healing is completed.

Clinical conclusions

- When taking advantage of improved implant designs and surfaces, well-selected recipient sites, adapted drilling protocols, and surgical techniques, today immediate implants and even immediate restoration of implants are reasonable and predictable treatment options.
- Clinical practice recommends not flushing or aspirating the bone cavity before and during the implant insertion.

References

1. Schroeder HE. Periodontium, a developmental and functional unit. In: Handbook of Microscopic Anatomy. Vol 5: The Periodontium. Berlin: Springer, 1986:12–22.
2. Bosshardt DD, Lang NP. The junctional epithelium: From health to disease. *J Dent Res* 2005;84:9–20.
3. Witte MB, Barbul A. General principles of wound healing. *Surg Clin North Am* 1997;77:509–528.
4. Coleman RW, Hirsh J, Marder VJ, Clowes AW, George JN (eds). Hemostasis and Thrombosis. Basic Principles and Clinical Practice. Philadelphia: Lippincott Williams & Wilkins, 2001.
5. Velnar T, Bailey T, Smrkolj V. The wound healing process: An overview of the cellular and molecular mechanisms. *J Int Med Res* 2009;37:1528–1542.
6. Salvi GE, Bosshardt DD, Lang NP, et al. Temporal sequence of hard and soft tissue healing around titanium dental implants. *Periodontol* 2000 2015;68:135–152.
7. Sculean A, Gruber R, Bosshardt DD. Soft tissue wound healing around teeth and dental implants. *J Clin Periodontol* 2014;41(suppl 15):S6–S22.
8. Villar CC, Huynh-Ba G, Mills MP, Cochran DL. Wound healing around dental implants. *Endod Topics* 2011;25:44–62.
9. Park JY, Gemmell CH, Davies JE. Platelet interactions with titanium: Modulation of platelet activity by surface topography. *Biomaterials* 2001;22:2671–2682.
10. Steinberg AD, Willey R, Drummond JL. In-vivo comparisons of clot formation on titanium and hydroxyapatite-coated titanium. *J Periodontol* 1992;63:990–994.
11. Schwarz F, Ferrari D, Herten M, et al. Effects of surface hydrophilicity and microtopography on early stages of soft and hard tissue integration at non-submerged titanium implants: An immunohistochemical study in dogs. *J Periodontol* 2007;78:2171–2184.
12. Potente M, Gerhardt H, Carmeliet P. Basic and therapeutic aspects of angiogenesis. *Cell* 2011;146:873–887.
13. Berglundh T, Abrahamsson I, Lang NP, Lindhe J. De novo alveolar bone formation adjacent to endosseous implants. *Clin Oral Implants Res* 2003;14:251–262.
14. Brånemark PI. Vital microscopy of bone marrow in rabbit. *Scand J Clin Lab Invest* 1959;11(suppl 38):1–82.
15. Albrektsson T, Brånemark PI, Hansson HA, Lindström J. Osseointegrated titanium implants. Requirements for ensuring a long-lasting, direct bone-to-implant anchorage in man. *Acta Orthop Scand* 1981;52:155–170.
16. Mavrogenis AF, Dimitriou R, Parvizi J, Babis GC. Biology of implant osseointegration. *J Musculoskelet Neuronal Interact* 2009;9:61–71.
17. Albrektsson T, Wennerberg A. On osseointegration in relation to implant surfaces. *Clin Implant Dent Relat Res* 2019;21(suppl 1):4–7.
18. Davies JE. Understanding peri-implant endosseous healing. *J Dent Educ* 2003;67:932–949.
19. Schüpbach P, Glauser R, Rocci A, et al. The human bone-oxidized titanium implant interface: A light microscopic, scanning electron microscopic, back-scatter scanning electron microscopic, and energy-dispersive x-ray study of clinically retrieved dental implants. *Clin Implant Dent Relat Res* 2005;7(suppl 1):S36–S43.
20. Wennerberg A, Albrektsson T. Effects of titanium surface topography on bone integration: A systematic review. *Clin Oral Implants Res* 2009;20(suppl 4):172–184.
21. Junker R, Dimakis A, Thoneick M, Jansen JA. Effects of implant surface coatings and composition on bone integration: A systematic review. *Clin Oral Implants Res* 2009;20(suppl 4):185–206.
22. Buser D, Schenk RK, Steinemann S, Fiorellini JP, Fox CH, Stich H. Influence of surface characteristics on bone integration of titanium implants. A histomorphometric study in miniature pigs. *J Biomed Mater Res* 1991;25:889–902.
23. Kuzyk PR, Saccone M, Sprague S, Simunovic N, Bhandari M, Schemitsch EH. Cross-linked versus conventional polyethylene for total hip replacement: A meta-analysis of randomised controlled trials. *J Bone Joint Surg Br* 2011;93:593–600.
24. Abrahamsson I, Berglundh T, Linder E, Lang NP, Lindhe J. Early bone formation adjacent to rough and turned endosseous implant surfaces. An experimental study in the dog. *Clin Oral Implants Res* 2004;15:381–392.

25. Watzak G, Zechner W, Ulm C, Tangl S, Tepper G, Watzek G. Histologic and histomorphometric analysis of three types of dental implants following 18 months of occlusal loading: A preliminary study in baboons. *Clin Oral Implants Res* 2005;16:408–416.
26. Glauser R, Rée A, Lundgren A, Gottlow J, Hämmerle CH, Schärer P. Immediate occlusal loading of Brånemark implants applied in various jawbone regions: A prospective, 1-year clinical study. *Clin Implant Dent Relat Res* 2001;3:204–213.
27. Lang NP, Salvi GE, Huynh-Ba G, Ivanovski S, Donos N, Bosshardt DD. Early osseointegration to hydrophilic and hydrophobic implant surfaces in humans. *Clin Oral Implants Res* 2011;22:349–356.
28. Bosshardt DD, Salvi GE, Huynh-Ba G, Ivanovski S, Donos N, Lang NP. The role of bone debris in early healing adjacent to hydrophilic and hydrophobic implant surfaces in man. *Clin Oral Implants Res* 2011;22:357–364.
29. Tabassum A, Meijer GJ, Wolke JG, Jansen JA. Influence of the surgical technique and surface roughness on the primary stability of an implant in artificial bone with a density equivalent to maxillary bone: A laboratory study. *Clin Oral Implants Res* 2009;20:327–332.
30. Tabassum A, Walboomers F, Wolke JG, Meijer GJ, Jansen JA. The influence of surface roughness on the displacement of osteogenic bone particles during placement of titanium screw-type implants. *Clin Implant Dent Relat Res* 2011;13:269–278.
31. Dhore CR, Snel SJ, Jacques SV, Naert IE, Walboomers XF, Jansen JA. In vitro osteogenic potential of bone debris resulting from placement of titanium screw-type implants. *Clin Oral Implants Res* 2008;19:606–611.
32. Glauser R, Schärer P. Sofort- und Frühbelastung. *Implantologie* 2000;8:121–126.
33. Glauser R, Sennerby L, Meredith N, et al. Resonance frequency analysis of implants subjected to immediate or early functional occlusal loading. Successful vs. failing implants. *Clin Oral Implants Res* 2004;15:428–434.
34. Glauser R, Lundgren AK, Gottlow J, et al. Immediate occlusal loading of Brånemark TiUnite implants placed predominantly in soft bone: 1-year results of a prospective clinical study. *Clin Implant Dent Relat Res* 2003;5(suppl 1):47–56.
35. Portmann M, Glauser R. Report of a case receiving full-arch rehabilitation in both jaws using immediate implant loading protocols: A 1-year resonance frequency analysis follow-up. *Clin Implant Dent Relat Res* 2006;8:25–31.
36. Szmukler-Moncler S, Piattelli A, Favero GA, Dubruille JH. Considerations preliminary to the application of early and immediate loading protocols in dental implantology. *Clin Oral Implants Res* 2000;11:12–25.

