

BUILDING BETTER BONE

A COMPREHENSIVE GUIDE TO GBR TECHNIQUES

▶ **Editor:**
ROBERTO ROSSI

▶ **Authors:**
ANTONIO BARONE
JOSEPH CHOUKROUN
SALVATORE D'AMATO
PETER JM FAIRBAIRN
EDOARDO FOCE
FILIPPO FONTANA
VINCENZO FOTI
HOWARD GLUCKMAN
ANDREA GRASSI
ARNDT HAPPE
SALAH HUWAIS
GIOVANNA IEZZI
EUGENIO LONGO
MICHELE ANTONIO LOPEZ
HASSAN MAGHAIREH
FABIO PERRET
ADRIANO PIATTELLI
ANDREA PILLONI
ALESSANDRO POZZI
LORENA RISPOLI
ROBERTO ROSSI
PAUL LEONHARD SCHUH
GIORGIO TABANELLA
HANNES WACHTEL

 QUINTESSENCE PUBLISHING

Berlin | Chicago | Tokyo
Barcelona | London | Milan | Mexico City | Paris | Prague | Seoul | Warsaw
Beijing | Istanbul | Sao Paulo | Zagreb

ISBN: 978-88-7492-096-9



© 2024 Quintessenza Edizioni

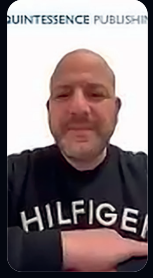


Quintessenza Edizioni S.r.l.
Via Ciro Menotti, 65 - 20017 Rho (MI) Italy
Tel.: +39.02.93.18.08.21
Fax: +39.02.93.18.61.59
E-mail: info@quintessenzaedizioni.it
www.quintessenzaedizioni.com

All rights reserved. This book or any part thereof may not be reproduced, stored in a retrieval system, or transmitted in any form or by any means, electronic, mechanical, photocopying, or otherwise, without prior written permission of the publisher.

Printed in Italy

*This book is dedicated my wife Dindy and my children
Arianna and Alessandro who I hope will forgive me
for all the weekends I stole from them to devote
myself to work, courses and congresses.
I dedicate it to the memory of my parents, especially
my father, he wrote poetry, I've always had a more
scientific than romantic soul so I hope he will be proud
of me even though I wrote about bone,
gums and teeth.*

Roberto Rossi



foreword

This book is the result of Roberto Rossi's passion for the clinic and for teaching, a great person and an excellent clinician.

I have been able to appreciate his qualities over the many years since his return from Boston University, where in the same school, even if at different times and thanks to Morris Ruben, great master of histology, we learned the biologic and histologic principles and healing mechanisms of periodontal therapy.

With the utmost attention and desire to clarify the various aspects of bone regenerative surgery, Roberto wanted to analyze the different methods for regenerating tissue and share the “tips and tricks” of the many techniques available today with colleagues.

With the highly explanatory material and video demonstrations in this book, Roberto shares his passion for periodontal therapy, combining his own experience and expertise with that of his colleagues, spreading knowledge for the benefit of colleagues and patients.

Congratulations, Roberto!
Thank you for your exemplary commitment.

With love, respect, and friendship,
Giano Ricci, MD, DDS, MScD

preface

The regenerative therapy called guided bone regeneration (GBR) was introduced about 30 years ago, exactly at the same time when I was completing my studies and specialization. Over the course of these 30 years, I have had the good fortune to experiment with many of the different techniques developed by experts and to accompany them with the use of many different biomaterials that have been introduced by manufacturers in the industry. Materials and methods have changed substantially, even if the biologic principles are and will always remain the same.

The advent of new technologies, from CBCT to digital technologies, have provided clinicians with very sophisticated new tools capable of facilitating the diagnosis and treatment planning of cases, from the simplest to the extremely complex ones.

The dental literature has widely covered the topic over these 30 years with publications in journals and books. However, these publications were often sponsored by companies and/or producers of a material or biomaterial.

Having the good fortune to participate in international courses and congresses around the world, over the years, I have been able to personally meet many of the experts in these issues and to engage in constructive discussions with them.

The pandemic was a sad period for humanity, but it gave us the opportunity to stop and be able to reflect, read, and review the available literature.

This gave rise to the idea of creating a book that would collect the ideas of clinicians whom I considered to be the most representative and experts in the various regenerative techniques. It would provide details to other colleagues about how different materials and methods could be applied with similar results, ranging from the use of autogenous bone to most of the best biomaterials offered by the market. It would be the first book to present all the different types of available grafting materials and techniques in one place. The result was a sort of recipe book, which explains each technique and describes the strengths, advantages, weaknesses, and limits of interventions performed with the same technique but with different products. I hope this will encourage readers to have the same curiosity that I have always had in venturing out to always test new technologies while also respecting the rules of the game.

All the Authors have added video tutorials of the individual step-by-step procedures in most of the chapters in the hopes that it will help to explain the tips and tricks of GBR and provide readers better predictability when they treat reconstructive surgery cases.

Roberto Rossi

acknowledgments

I would like to thank all those who have in any way influenced my career and my choices, especially in work.

I would like to start with Prof Giorgio Blasi, who triggered my interest in periodontology, and Prof Hyman Smukler, who was my teacher for 3 years at Boston University, as well as Prof Morris Ruben, Dr Zeina Majzoub, and Dr Veronique Cohen. They have instilled in me the desire to always be precise and excellent in all aspects of the surgical phase of treatment and in case documentation.

I also want to thank Dr Giano Ricci, who welcomed me into his office when I was still a “kid” and was a guide for 30 years, a friend, and a fantastic adviser. I can’t even enumerate all the colleagues and friends from whom I learned many of the tips and tricks you’ll read in this book because that alone could fill a whole chapter. I would like to make a dedication to all those people who have worked in my clinics over the years and have helped me build many of the cases you will see in the book; Nadia, Luisa, Vanda, Deborah, Francesca, and Milva, without your constant help everything would have been harder. And then I cannot fail to thank my current “team”: Dr Alessandro Conti and Davide Bertazzo, Nino Squadrito, and Andrea De Marchi, but also all the dear friends who have collaborated in the past and contributed to the growth of my clinics and professional life. Above all, thank you to Drs Emanuele Risciotti, Riccardo Ammannato, and Tommaso Cantoni. Thanks also to Drs Castellaro, Mocini, Galeano, and Brovero, who have taken care of maintaining the cases we have treated in the last 30 years.

I would like to thank all those friends who have happily agreed to participate in this adventure; the result seems excellent to me and could only be accomplished with great teamwork. A huge thank you to Maria Grazia Monzeglio of Quintessence, who believed in and supported this project, Cristina Reina for her indisputable “sewing” work, and to the Haase family.

Last but not the least all the friends that cooperated with me in the preparation of this book, without their great work and wonderful material this book would simply not exist.

Roberto Rossi

authors



ROBERTO ROSSI Dental Degree at the University of Genova in 1987, followed by a postgraduate program in Periodontology at Boston University (1989-91) where he received his Master of Science in Dentistry in Periodontology in 1992. After returning in Italy is running his practice limited to periodontology and esthetic dentistry in Casale Monferrato and Genova. He has been involved in teaching at graduate and post graduate programs in several universities in Italy and abroad. Has intensively participated in research projects with different groups in the fields of guided tissue regeneration, guided bone regeneration and esthetics. He's an active member and president-elect of the Italian Academy of Esthetic Dentistry (IAED), a certified member of the European Society of Cosmetic Dentistry (ESCD), a certified member of the Italian Society of Periodontology (SidP), member of the Italian Academy of Osseointegration (IAO), founding member and past vice-president of the Bone Biomaterials and Beyond (BBB) academy, honorary member of the Bohemian Society of Implantology, former board member and secretary of the Boston University Italian alumni association. Author of more than 50 publications and book chapters.



ANTONIO BARONE, DDS, PhD, MSc, FIC, Doctor of Dental Surgery, Doctor of Philosophy in Dental Sciences, Specialist in Oral Surgery, European Master Degree in Oral Surgery and Medicine. Fellow of the International College of Dentists. Full Professor, Head of Oral Surgery and Implant Dentistry, Department of Surgical, Medical, Molecular and of the Critical Area Pathologies, University of Pisa, Italy. University-Hospital of Pisa, Santa Chiara Hospital, Pisa, Italy. Adjunct Professor, Department of Oral and Maxillofacial Surgery, SUNY at Buffalo, USA. Past-President of the Bone, Biomaterial and Beyond Academy. Past-President of the European Federation of Oral Surgery Societies. Past-President of the Italian Society of Oral Surgery and Implantology.



JOSEPH CHOUKROUN MD, University of Montpellier, France 1979. Specialist in Anesthesiology & Pain management. Owner of Private Pain Clinic, Nice France. President of SYFAC, international symposium on growth factors. Inventor of the PRF techniques. Author of several scientific publications. International speaker.



SALVATORE D'AMATO Graduated in medicine and surgery from the University of Naples Federico II in 1982 and subsequently qualified to practice the dental profession. His professional training is achieved through an academic path where since 1982 he has been first an internal doctor, then a specialist in maxillofacial surgery, a technical officer, a university researcher and today an associate professor of maxillofacial surgery belonging to the multi-disciplinary department of Medical-Surgical and Dental Specialties of the University of Campania Luigi Vanvitelli. During the first years he dedicated himself mainly to oral surgery for oral pathology but, since the end of the 80s, with the advent of implantology in the daily routine of everyday dentistry, he developed a notable interest in this discipline considering it strictly dependent on an interdisciplinary approach. Therefore, his training was completed by following fellowships, seeing professor programs, scientific societies and refresher courses in pre- and post-implant surgery, periodontium and prosthetics. Today he directs the Rehabilitation Surgery Unit of the Oral-Maxillo-Facial District of the Luigi Vanvitelli University Hospital and the II level Master of Oral Implantology. He is also an Active member of the European Academy Esthetic Dentistry EAED, President of the Italian Academy of Esthetic Dentistry IAED. Active member of the Italian Academy Osseointegration IAO. Active Member of the International Academy for Digital Dental Medicine. Member of the Italian Society of Maxillofacial Surgery SICMF. He dedicates much of his freelance activity to implant-prosthetics. Author of numerous scientific publications in oral surgery, implant surgery and prosthetics published in national and international journals.



PETER JM FAIRBAIRN Peter has been placing dental implants since 1990 and worked solely with Synthetic (Alloplast) particulate graft materials for the last 24 years. He is a honorary life member and past Director of the ADI (UK) as well as past president of the London dental fellowship. Peter has numerous Pubmed publications on bone regeneration and has lectured in over 50 countries on the topic. He is also a visiting professor at the University of Detroit Mercy school of Dentistry, MI, USA.



EDOARDO FOCE University of Genoa, Italy. Graduated In Medicine & Surgery and completed postgraduate specialization In Dentistry and Prosthodontics. 1988–2019 active member of the Italian Society of Conservative Dentistry, the Italian Society of Endodontics, the European Society of Endodontics, the Italian Academy of Prosthetic Dentistry, the Italian Society of Oral Surgery and Implantology and the Italian Society of Periodontology & Implantology. Currently active member of the Italian Society of Periodontology & Implantology. Alumnus of De Chiesa - Pescarmona, Saluzzo Institute and Carnevale - Di Febo, Bologna Mascarella Institute. San Raffaele University, Milan, Italy. Visiting Professor of Periodontology (2009–2013). Guest speaker at conferences and congresses on a number of dental specialties. Co-author of articles on Implantology and Implant Prosthodontics; co-author of Chapter X of the Italian Society of Oral Surgery and Implantology's Manual of Oral Surgery (ed. Elsevier). Sole author of Endo-Periodontal Lesions (ed. Quintessence Publishing 2011). Co-author of a monograph in Italian on VEP - Vertical Edgeless Preparation: la dominanza parodontale nella preparazione protesica. Quintessence Publishing Italia, 2021). Currently private practice in La Spezia, Italy, dealing with multidisciplinary dentistry with a special interest in prosthetic-periodontal cases and dental implantology.



FILIPPO FONTANA Graduated in dentistry with the score of 110/110 *com laude* at the University of Milan in 2000. Master of science in oral surgery with the score of 70/70 *cum laude* at the same University in 2009. Visiting Professor at the School of Oral Surgery of the University of Milano. Research Associate of the Eng.A.B. Growth Factors and Bone Regeneration Research Chair of the King Saud University in Riyadh (Saudi Arabia). Since 2000 he is clinical assistant at the Department of Implantology of the University of Milano directed by Prof Maiorana. Awarded one year scholarship in 2002, he was research assistant at the Department of Oral Medicine, Infection and Immunity of Harvard School of Dental Medicine (Boston, MA, USA). Research assistant of the Institute for Dental Research and Education (IDRE) directed by Prof. Massimo Simion. Author of several articles, he focuses his clinical activity on implantology with particular care to bone regeneration.



VINCENZO FOTI Graduated in Medicine and Surgery *magna cum laude* at University of Genova, Italy. Diploma in Periodontology and Implantology at University of Nice, France. Speaker at national and international congresses. Author of scientific papers and book chapters. Member of the Italian Society of Periodontology and Implantology (SIdP). Member of the Italian Academy of Osseointegration (IAO). Active Member of Bone Biomaterials & Beyond Academy (BBBA). Founder of International Academy of F.I.R.S.T. (IAF). Since 1999 he has been using the fibrin sealant-based bone regenerative technique. In 2016 he devised and in 2020 he published the F.I.R.S.T. technique (Foti V, Rossi R. *Mod Res Dent.* 2020).



HOWARD GLUCKMAN Prof Gluckman is an internationally renowned dental practitioner, implantologist, author, and lecturer who has been in the industry for nearly three decades. Not one to rest on his laurels, Prof Gluckman recently completed his PhD, titled "Partial Extraction Therapy: Past, Present and Future" passing Summa Cum Laude at the University of Szeged, Hungary, under the supervision of Professor Katalin Nagy. Not only is Prof Gluckman also Adjunct Assistant Professor for the University of Pennsylvania School of Dental Medicine but was recently bestowed to the honour of Adjunct Professor at the University of the Western Cape in South Africa and Visiting Professor at the University of Sarajevo - Faculty of Dentistry with dental clinical centre. In addition to running his full-time private practice in Cape Town, Prof Gluckman is also the co-founder and director of Implant & Aesthetic Academy (IAA), which just this year celebrates its 20th year. To date, it's the only private postgraduate training facility of its kind.



ANDREA GRASSI Graduated in 2004 in "Dentistry and Dental Prosthetics" at the University of Modena and Reggio Emilia. From 2005 to 2007 he attended the "Second level International Biennial Master in Oral Surgery and Implantology" at the University of Verona. Speaker at national and international courses and conferences, he mainly dedicates himself to reconstructive surgery with a flapless approach, periosteal inhibition technique, implant surgery and implant prosthesis. Co-author of the book: "Next-Generation Biomaterials for bone & Periodontal Regeneration", by Richard J. Miron and Yufeng Zhang (Quintessence Publishing USA, 2019).



ARNDT HAPPE Priv-Doz Dr Med Dent. Renown Private & Referral Practice in Münster, Germany, treating Implant, Perio, Restorative and Esthetic Cases. Research fellow and external lecturer at the University of Cologne and Ulm, both in Germany.



SALAH HUWAIS, DDS. 1990 DDS, University of Aleppo, School of Dentistry. 1997 Periodontics and Implantology Surgical Training, University of Illinois at Chicago, College of Dentistry. Recipient, AAIDF, Isaih Lew Research Award. Diplomate, The American Board of Periodontology. Diplomate, The American Board of Implantology. Fellow, The American Academy of Implantology. Adjunct assistant Professor, University of Illinois, Post-Grad Periodontics. University of Pennsylvania, Post-Grad Periodontics. Founder of the Osseodensification and the inventor of the Densah® Bur technology.



GIOVANNA IEZZI, DDS, PhD, Specialist in Orthodontics. She is Full Professor and Director of the Laboratory of Implant Histology and Biomaterials at the Department of Medical, Oral and Biotechnological Sciences, University G. d'Annunzio of Chieti-Pescara, Italy. Prof. Iezzi has coauthored about 354 papers (8,495 citations and 44 h index, SCOPUS October 2023) in international peer-reviewed Journals. Her research is oriented to the study of soft tissues and bone tissue in relation to dental implants and biomaterials for bone regeneration. Furthermore, through interdisciplinary methodological approaches she has tested new techniques on the study of connective tissues. Active member of the Italian Academy of Osseointegration (IAO), Biomaterials & Beyond Academy (BBBA), Italian Society of Dental Surgery (SIdCO) and member of Academy of Non Transfusional Hemo-Components (ANTHEC).



EUGENIO LONGO Active member of IAED (Italian Academy of Esthetic Dentistry), IAO (Italian Academy of Osteointegration). Visiting professor University of Genoa. International Lecturer on periodontology, implantology and oral surgery.



MICHELE ANTONIO LOPEZ Graduated in Medicine and Surgery at the Università Cattolica del Sacro Cuore in Rome in 1989, he obtained a specialization in Odontostomatology in 1993. Author of over 50 scientific articles on prosthetics and implantology. Adjunct professor at the “A. Gemelli” Faculty of Medicine and Surgery of the School of Specialization in Oral Surgery, Università Cattolica del Sacro Cuore in Rome. (Director Prof A. D’Addona). Visiting Professor at Goradze International University in the Degree Course in Dentistry and Dental Prosthetics (Director Prof P. Di Domizio). Professor and member of the scientific committee of the II level Master in Basic and Advanced Implant Surgery and Prosthetic Implant Rehabilitation. Gemelli Polyclinic Università Cattolica del Sacro Cuore in-Rome (Director Prof A. D’Addona). Oral surgeon in Integrated Therapies UOS Otolaryngology (Director Prof M. Casale) Policlinico Campus Biomedico of Rome expert in the management of the maxillary sinus. He regularly gives lectures and presentations at conferences in Italy and abroad. Active member of the Bone Biomaterials & Beyond Academy. Author of an invention patent: Tool for inserting pins into bone tissue and pin holder. Dr. Lopez works in his private practice in Rome, exclusively in the field of reconstructive prosthetic surgery and implantology.



HASSAN MAGHAIREH, Associate Professor in Oral Surgery & Implant Dentistry, College of Medicine & Dentistry - Ulster University, Birmingham, UK.
ITI Fellow.
Head of The Scientific Committee, The British Academy of Implant & Restorative Dentistry.
Leeds dental Implant & Cosmetic Clinic, Leeds, UK.



FABIO PERRET 2001 Graduated DDS at the University of Turin (Italy). 2007-2008 Post-graduate program in Periodontology (University of Turin). 2010-2011 International Post-graduate Certificate in Implantology and Oral Rehabilitation (New York University College of Dentistry). Lecturer and author of international scientific papers about hard and soft tissue regeneration. Private clinical practice and education programs in periodontology, oral implantology and guided tissue regeneration.



ADRIANO PIATTELLI MD, DDS, DrHC, DrHC, is currently Full Professor, School of Dentistry, San Camillo International University of Health Sciences (UniCamillus), Rome, Italy. He was Full Professor in the Dental School of the University of Chieti-Pescara, Italy, from 1997 to 2021, and an Associate Professor in the same University from 1988 to 1997. From 1997 to 2009 he was Dean and Director of Studies and Research, Dental School, University of Chieti-Pescara, Italy. He graduated in Medicine and Surgery at the Catholic University in Rome in July 1975. He took the Specialty Board of General Surgery at Chieti University in July 1980 and the Specialty Board of Dentistry at Rome “Sapienza” University in 1988. Since 1990 he is a Consultant for the Italian National Health Service. In the years 2003-2005 he was President of the Italian Society of Osseointegration (SIO). He is a Member of the Academy of Osseointegration (AO), and of the Continental European Division (CED) of the International Association for Dental Research (IADR). He is Member of the Board of the Journal of Oral Pathology and Medicine (1993-1999), of Clinical Implant Dentistry and Related Research (2002) Implant Dentistry (2014), and of Clinical Oral Investigations (2014). He is Reviewer of the following Journals: Clin Oral Impl Res, J Clin Periodontol, Clin Impl Dent Relat Res, J Biomed Mater Res – Applied Biomaterials, J Biomed Mater Res, Biomaterials, Oral Diseases, Histol Histopathol, Cell Tissue Res, Lancet Oncology, J Endodon, Acta Biomaterialia, Cell Biology International, J Oral Rehabil, Oral Oncology, J Nanomaterials. Prof Piattelli has co-authored 941 papers in international peer-reviewed Journals (SCOPUS, October 2023); most of these papers have dealt with Implant Dentistry and Biomaterials. Prof Piattelli H Index is 75, his citations are 27749. Prof Piattelli main research interests have been immediate loading, bone response to different biomaterials, bone response in human implants retrieved in several different clinical and anatomic conditions. Prof Piattelli received in November 2015 a *Honoris Causa* degree from the University of Valencia in Spain, and in October 2016 an *Honoris Causa* degree from the Universidad Catolica de San Antonio de Murcia (UCAM), Murcia, Spain. In June 2016 he received in Seoul, ROK, the IADR 2016 Distinguished Scientist Award for Implant and Prosthodontics. In 2016 he was the Editor of “Bone response to dental biomaterials”, a book published by WoodHead Publishing, an imprint of Elsevier. From 1995 to 1999 he was Honorary Senior Lecturer at the Eastman Dental Institute in London, UK. From January 2017 he has a Chair of Biomaterials Engineering at the UCAM in Murcia. Since 2018, he has been Visiting Professor at the Dental School of the University of Belgrade, in Serbia. Since December 2022, he is Visiting Professor at the Unisul University, Florianopolis, Santa Catarina, Brasil, and from March 2023, Visiting Professor of the University of Guarulhos (UnG), Guarulhos, Sao Paulo, Brasil. Prof Piattelli, in the last two years, has founded a Society, called Adriano Piattelli Research Group (APRG), dedicated to the support of researches in the medical and dental fields, comprising *in vitro*, experimental and clinical researches, and also an Association, called Adriano Piattelli Study Club (APSC), dedicated to the dissemination of knowledge in an international setting.



ANDREA PILLONI Full Professor and Director of the Postgraduate Program in Periodontology at Sapienza, University of Rome. Part-time Faculty as Adjunct Associate Professor at the Ohio State University Department of Periodontology, College of Dentistry.
Board Certified in Periodontology for the Italian Society of Periodontology. Private practice in Rome, limited to Periodontology, since 1993.



ALESSANDRO POZZI Prof Alessandro Pozzi has been in practice since 1997. Clinical Researcher in Surgical navigation and Advanced Dental Technologies of the University of Rome Tor Vergata. Adjunct Clinical Associate Professor at Goldstein Center for Esthetics and Implant Dentistry, Augusta University USA. Part-Time Faculty Harvard School of Dental Medicine, Department of Restorative & Biomaterials Sciences, USA. PhD degree, Doctoral School of Clinical Medicine, University of Szeged, Hungary. Specialist in Orthodontics and TMJ dysfunctions, Dual-Specialist Diploma in Surgical and Prosthetic Implant Dentistry, Academy of Osseointegration (AO). Researcher and scientist, widely published, he was awarded the 2013 Judson C. Hickey Scientific Writing Award from the Journal of Prosthetic Dentistry and in the 2021 he received the Best Original Paper Award by the Japanese Society of Prosthodontics. In 2020, he was entitled with the prestigious Fellowship status of the Academy of Osseointegration (AO) for his commitment to the field of Osseointegration. Co-Editor with PK Moy and John Beumer of the textbook Fundamentals of Implant Dentistry, Quintessence Publishing. Editorial Board Member of International Journal Oral Implantology (IJOI), Journal of Esthetic Restorative Dentistry (JERD) and International Journal of Oral Maxillofacial Implants (JOMI). Active member of the Italian Academy of Esthetic Dentistry (IAED). Besides lecturing internationally in the most prestigious congresses and academies, Pozzi Institute in Rome is one of the 9 qualified international training centers that meet Academy of Osseointegration's strict academic and training criteria. He holds training courses with emphasis on guided and navigation-assisted implant-surgery and digitally assisted immediate function and esthetics.



LORENA RISPOLI, DDS MSc PhD. Graduated from the Dental School at "Sapienza" University of Rome, Italy, in 2001, she was awarded PhD in Oral Science, in 2005 and earned a MSc Certificate in Oral Surgery, in 2008, conferred by the same institution. She was Lecturer and Clinical Instructor at "Sapienza" University at the II level MSc International Programs on Implant Dentistry and for Oral and Maxillo-Facial Surgery and Cranio-Facial Anatomy for the MSc program in Orthodontics at Catholic University, Rome. She has lectured at national and international associations dental meeting and she is co-author of several publications on surgical topics. Since 2021 to date she is involved as expert in periomedicine in a multidisciplinary research project at Humanitas University, Milano. For the accomplishment of these studies Dr. Rispoli daily clinical activity is focused particularly on surgical procedures aimed to regenerate the lost tissues of the periodontal apparatus using innovative materials and techniques.



PAUL LEONHARD SCHUH received his dental degree from the private University Witten/Herdecke in 2012. Before this, he completed a three-year dental technician program in Bamberg (Germany). At the dental clinic of Witten/Herdecke University, he worked as a research associate in the department of Prosthodontics and dental Technology of Prof Dr Andree Piwowarczyk. In 2013 he joined the team of Dr Wolfgang Bolz and Prof Dr Hannes Wachtel at Implants-Dental Clinic in Munich for a postgraduate program in Periodontology and Implantology. Dr Schuh was lecturer at the Institute for Periodontology and Implantology Munich (IPI) and has published scientific articles in journals for implant and esthetic dentistry. Since 2014 he has been an associate fellow and an expert of the Foundation for Oral Rehabilitation (FOR) and is lecturer of the Dresden International University "Master of science of periodontology and implant-therapy" in cooperation with the German Society of Periodontology. Since 2021 he has been founder of his own digital dental office "artedent" in Munich. Dr. Schuh is Ambassador for the Digital Dentistry Society, Germany.



GIORGIO TABANELLA is a Diplomate of the American Board of Periodontology, Active Member of the Italian Academy of Esthetic Dentistry and author of the book "Retreatment of failures in dental medicine", Quintessence Publishing, 2019. He graduated from the University of Southern California, Los Angeles-USA where he obtained the Certificate in Periodontics as well as the Master of Science in Craniofacial Biology. Dr Tabanella lectures in Europe, Asia, Middle East, South Africa as well as in the US on implant and periodontal surgery, aesthetic management in dental implant and periodontal therapy, peri-implant bone remodeling, soft and hard tissue reconstruction around natural teeth and implants as well as the re-treatment of failures.



HANNES WACHTEL Dental degree at the University of Tübingen (Germany) in 1982, followed by a postgraduate program in prosthodontics at the University of Southern California (1982-83). He served as associate professor in the Department of Periodontology, University of Berlin (1984-1994), receiving his PhD (1992) as well as professor in the postgraduate program of Periodontology at Sahlgrenska University in Gothenburg. Since 1994, he is heading a private dental clinic in Munich, since 2022 together with Dr. Maischberger, devoted to periodontology, implantology, and restorative dentistry. In the editorial board of several journals, he is member of numerous dental societies including active member of the EAED, and has authored/co-authored over 100 scientific articles and book chapters. Currently, he is professor at the Charité University of Berlin, and at the Sahlgrenska University of Gothenburg.

contributors

Marko Blašković, Samvel Bleyan, Paolo Carosi, Elisa Choukroun, James Chow, Chiara Cinquini, Emira D'Amico, Natalia Di Pietro, Željka Perić Kačarević, Stefania Lepore, Carlo Mangano, Lorenzo Marini, Peter K. Moy, Rodrigo Neiva, Morena Petrini, Tania Vanessa Pierfelice, Giancarlo Pongione, Patrick Rider, Svenja Rogge, Mariana Andreas Rojas, Mario Santagata, Dražen Tadić, Margherita Tumedei, Nicola Alberto Valente, Frank Zastrow.

summary

▶▶▶ <i>Foreward</i>	V
<i>Preface</i>	VI
<i>Acknowledgments</i>	VII
<i>Authors</i>	VIII
▶▶▶ CHAPTER 1	
GUIDELINES AND SCIENTIFIC BACKGROUND OF GBR	2
Biologic basis of GBR	3
Barrier membranes	4
Clinical applications	6
Surgical technique	8
Conclusions	10
▶▶▶ CHAPTER 2	
WOUND HEALING: FROM BASIC MECHANISMS TO SOFT TISSUE HEALING IN ORAL SURGERY	14
BONE BIOLOGY AND WOUND HEALING	15
Bone healing	15
Wound healing	18
SOFT TISSUE HEALING IN BONE RECONSTRUCTIVE SURGERY	21
Exploring rapid and scarless wound healing in oral soft tissues: the “time” and “quality” factors in oral mucosal healing	21
Postsurgical monitoring of soft tissue healing	22
Clinical implications of poor soft tissue healing	27
Personalized medicine: is there a translational gap applying in molecular understanding?	27
▶▶▶ CHAPTER 3	
CLASSIFICATION AND GUIDELINES FOR TREATMENT OF BONY AND SOFT TISSUE DEFECTS	30
Case study and evaluation	31
Classification of bony defects	31
Subclassification of bony defects	36

▶▶▶ CHAPTER 4	
FRESH EXTRACTION SOCKET MANAGEMENT: THINKING IN AND OUT OF THE BOX	40
THINKING IN THE BOX	41
Immediate implants	41
Early implant placement	42
Alveolar ridge preservation	42
Summary	44
Case report 1	45
Case report 2	50
Tips & tricks	54
THINKING OUT OF THE BOX	55
Periosteal Inhibition in Edentulous Sockets: A New Paradigm	55
Surgical protocol	56
Case report 3	57
Case report 4	61
Tips & tricks	64
▶▶▶ CHAPTER 5	
OSSEODENSIFICATION FOR RIDGE EXPANSION: CLINICAL PROTOCOLS AND CASE REPORTS	66
Case report 1	69
Case report 2	75
Case report 3	80
Tips & tricks	86
▶▶▶ CHAPTER 6	
RESORBABLE AND NONRESORBABLE MEMBRANES	90
Decision criteria in GBR	91
Case report 1	93
Case report 2	97
Tips & tricks	101
▶▶▶ CHAPTER 7	
RATIONALE FOR THE USE OF AUTOGENOUS GRAFTS, ALLOPLASTS, AND XENOGRAFTS	102
Anorganic Bovine Bone (ABB)	104
Porcine Bone (PB)	104
Equine Bone (EQ)	105
Biphasic Calcium Phosphate (BCP)	106
Porous Hydroxyapatite (HA)	106
Engineered Hydroxyapatite (ENGIpore)	106
Dense Hydroxyapatite (HA)	107
Biocoral	107
Calcium Sulfate (CaS)	108
Poly(lactic/polyglycolic acid)	108
Conclusions and useful tips	108

▶▶▶ CHAPTER 8	
AUTOGENOUS BONE GRAFTING IN THE POSTERIOR EDENTULOUS MANDIBLE WITH THE KHOURY TECHNIQUE: INDICATIONS, CONTRAINDICATIONS, AND LIMITATIONS	110
Case report 1	112
Case report 2	117
Tips & tricks	123
▶▶▶ CHAPTER 9	
INNOVATIVE AUTOGENOUS BONE GRAFTING TECHNIQUES	124
Palatal Bone Block Graft	125
Case report 1	126
Tips & tricks	135
Case report 2	136
Tips & tricks	144
▶▶▶ CHAPTER 10	
USE OF HETEROLOGOUS LAMINA IN THE ESTHETIC ZONE: SITE SPECIFIC TREATMENT OPTIONS DEPENDING ON SITE MORPHOLOGY	146
Case report 1	148
Case report 2	152
Case report 3	155
Tips & tricks	158
▶▶▶ CHAPTER 11	
OCCLUSIVE TITANIUM BARRIERS FOR GBR	160
Surgical technique	162
Case report 1	163
Case report 2	168
Tips & tricks	177
▶▶▶ CHAPTER 12	
CORTICAL LAMINA XENOGENEIC BONE MEMBRANE: INDICATIONS, CONTRAINDICATIONS, AND LIMITATIONS	180
Case report 1	183
Case report 2	190
Tips & tricks	197

▶▶▶ CHAPTER 13	
CORTICAL LAMINA IN HORIZONTAL AND ANTERIOR DEFECTS: THE MULTILAYER TECHNIQUE	198
Indications	199
Contraindications	199
Surgical technique	201
Case report 1	202
Case report 2	206
Tips & tricks	209
▶▶▶ CHAPTER 14	
FIBRINOGEN-INDUCED REGENERATION SEALING TECHNIQUE (F.I.R.S.T.)	210
Fibrin sealant	211
Fibrinogen-Induced Regeneration Sealing Technique (F.I.R.S.T.)	211
Case report 1	212
Case report 2	220
Tips & tricks	227
▶▶▶ CHAPTER 15	
USE OF CORTICAL LAMINAS FOR BONE LAYERING AND BONE-INTO-BONE TECHNIQUES	228
Case report 1	230
Case report 2	234
Tips & tricks	240
▶▶▶ CHAPTER 16	
OSTEODISTRACTION FOR RIDGE AUGMENTATION: PRINCIPLES, INDICATIONS, AND CONTRAINDICATIONS	242
Objectives of crestal distraction	246
Surgical technique	246
Benefits	258
Disadvantages	262
Discussion	262
Conclusions	264
Indications	264
Tips & tricks	265
▶▶▶ CHAPTER 17	
GBR FOR MAXILLOFACIAL AND CONGENITAL DEFECTS	266
Esthetic approach to the management of residual alveolar cleft	267
Case report 1	268
Tips & tricks	279
Discussion	280
Conclusions	280

▶▶▶ CHAPTER 18	
DIGITAL VERTICAL AND HORIZONTAL BONE BLOCK GRAFTING	282
Workflow	284
Case report 1	285
Case report 2	294
Tips & tricks	304
▶▶▶ CHAPTER 19	
IMMUNE MODULATION WITH CALCIUM PHOSPHATE ALLOPLAST. UP-REGULATED, MEMBRANE FREE HOST BONE REGENERATION	306
Case report 1	309
Case report 2	314
Tips & tricks	318
▶▶▶ CHAPTER 20	
USING DIGITAL DENTISTRY TO BUILD SOFT AND HARD TISSUES FOR FUNCTION AND ESTHETICS	320
Case report 1	322
Case report 2	328
Tips & tricks	334
▶▶▶ CHAPTER 21	
EVOLUTION OF XENOGENEIC BONE MEMBRANES: FLEX CORTICAL SHEET	336
Case report 1	338
Case report 2	343
Tips & tricks	346
▶▶▶ CHAPTER 22	
DIGITALLY ASSISTED SOFT TISSUE AND BONE SCULPTING FOR PK1 (PINK-FREE) FULL ARCH PROSTHESIS	348
Principles	349
Interplay between the prosthesis and the hard and soft tissues	349
Biologic pontic design	351
Digitally Assisted Soft tissue Sculpturing (DASS) technique	352
Smiling Scan technique	352
Prosthetic- and soft tissue-driven implant planning	354
Surgical phases	355
Role of biomaterials	361
Differences from other protocols	362
Conclusions	363
Tips & tricks	366

▶▶▶ CHAPTER 23	
MAGNESIUM: THE NEXT GENERATION OF BIOMATERIALS IN REGENERATIVE DENTISTRY	368
Magnesium	369
Magnesium barrier membranes	371
Case report 1	374
Magnesium fixation screws	376
Case report 2	378
Tips & tricks	380
▶▶▶ CHAPTER 24	
OXIDATIVE STRESS AND OSTEOIMMUNOLOGY: THE TWO MISSING PIECES OF THE ORAL OSSEOINTEGRATION PUZZLE	382
Oxidative stress	383
Osteoimmunology	385
Immunity and the immune system	385
Prevention of oxidative stress during osseointegration/oral surgery	385
Growth factors and oxidative stress	387
Conclusion	387



Chapter 9

**Innovative
autogenous bone
grafting techniques**

Howard Gluckman



PALATAL BONE BLOCK GRAFT

Autogenous bone remains the gold standard in bone augmentation techniques. However, the second site morbidity remains a barrier to this technique for clinicians and patients. The palate presents a unique opportunity when augmenting the anterior maxilla. Alfaro-Hernandez et al² were the first to use the palate to harvest cores of bone as a socket preservation technique in the same site as an extracted tooth. The cores were removed with a trephine and secured into the extraction socket with a mallet. The method showed successful outcomes and bone volume maintenance to place implants. Hassani et al,^{1,3} measured the bone volume in dry skulls and offered the anterior palate as a viable option for autogenous bone harvesting. Gluckman et al⁴ utilized trephines and piezoelectric surgery to harvest bone blocks from the palate. This case series illustrated the successful use of bone blocks to augment dehiscence defects in the anterior maxilla with a 1- to 6-year follow-up. This technique was later modified to incorporate the split bone block technique described by Khoury.⁵ The palatal bone is a dense cortical bone with an underlying layer of medullary bone similar to the symphysis. The palate proves to be an area where one can harvest bone cores or plates with a trephine, bone blocks using piezoelectric surgery, or autogenous bone scrapings using bone harvesters like the AutoMax (MegaGen). The bone can be utilized as a solid block or mortised into particulate bone and used for guided bone regeneration (GBR) techniques. Trephines can be used perpendicularly to the palatal surface if the roots are out the way or parallel to the palate if the palate is very deep with a prominent palatal shelf. Piezoelectric surgery is a safer option for harvesting as it allows guidance of the cutting surface away from the underlying roots. In a triangular palate, the initial occlusal incision is vertical and parallel to the root surfaces; the two vertical releasing cuts and the apical cut are perpendicular to the bone surface.

This will provide a triangle-shaped block that can be further shaped to fit the defect or split into two to create two plates for the split bone block technique.

Anatomical limitations

When harvesting from the palate, care should be taken not to damage any underlying structures, like the teeth, sinus, nasal passages, and incisive canals. CBCT analysis of the area is essential to familiarize oneself with the local anatomy and prevent accidental damage to the vital structures. Perforation of the sinus or nasal passage has no long-term complications. The short-term complication is bleeding, which needs to be addressed before final closure of the flap. Damage to the adjacent teeth is permanent and must be avoided. Teeth in labioversion with the roots situated buccally usually present the safest area of harvest as they are distant from the palate, providing room to harvest. In cases where the palate is highly vaulted and the alveolus walls are parallel, the roots are incredibly close to the palatal bone. They, therefore, cannot be used as a harvest site unless it is an edentulous area. A more triangular palate is ideal as the teeth are buccally positioned, and the broad base provides a perfect spot from which to harvest the bone. In edentulous areas, all cuts can be perpendicular to the palatal surface.

Flap management

The most straightforward flap for palatal bone harvesting is a sulcular flap that extends from pre-molar to premolar. Alternatively, a releasing incision can be made; however, it is essential to ensure that the release is made to create a broad base. Releasing straight down the palate creates a narrow-based flap, which carries the risk of flap necrosis due to poor blood supply. The flap can be sutured using simple interrupted sutures or a continuous suture.

► **Case report 1: Figs 1 to 36.**

► **Case report 2: Figs 37 to 75.**

CASE REPORT

1

Patient age 39, male

The patient was referred with a provisional three-unit partial denture from the maxillary right lateral incisor to left central incisor with a pontic in the right central incisor area (**Figs 1 to 3**).

The fixed partial denture on these teeth had been present for a few years and had begun coming loose. It was decided that an implant should be placed in the right central incisor area with single crowns on the adjacent abutments to reduce the stress on the left central incisor, which had a large post and core, and to facilitate easier oral hygiene with single crowns to replace the fixed partial denture. Clinical and radiographic examination revealed the adjacent right lateral incisor and left central incisor to be healthy and stable (**Figs 4 and 5**).

CBCT analysis revealed a resorbed ridge in the area of the right central incisor, requiring bone augmentation to create stable bone to surround the implant (**Fig 6**). The vertical height of the bone was adequate, so only buccal augmentation was required (**Figs 7 and 8**).

Medical history: No contributing medical history. The patient was healthy, on no medications, and had no contraindications to any surgical procedures.

Esthetic needs: Although the teeth involved were anterior teeth, he had a very low lip line, and hence the gingival margins and gingival levels did not play a significant role in the decision making for the case. The only esthetic factor was his incisal line, which was managed by his referring dentist.

Proposed treatment plan

Placement of an implant in the right central incisor area with the simultaneous autogenous bone graft at the time of implant placement was proposed. Due to the favorable anatomy, the palate was chosen as a harvest site for an autogenous Khoury bone block. The graft site would be left for about 4 months for bone healing and implant integration before the implant was exposed using an esthetic tunnel exposure technique, followed by the fabrication of a provisional crown to allow the correct contouring of the soft tissue prior to the final crown placement.

Surgical technique

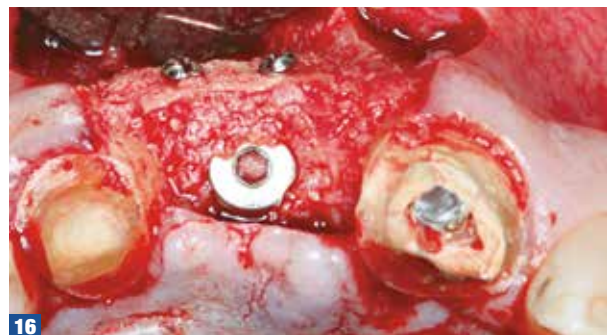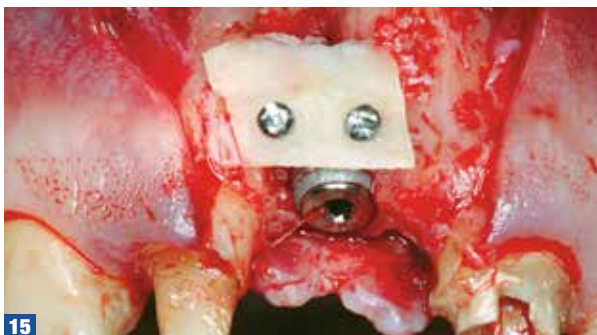
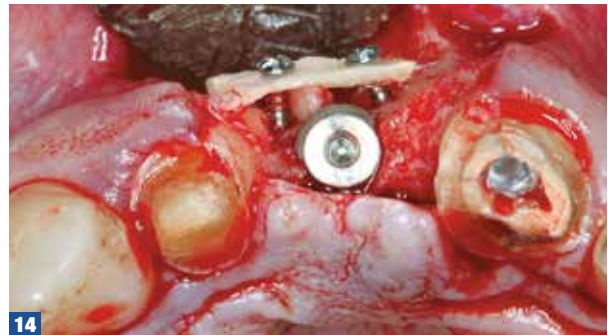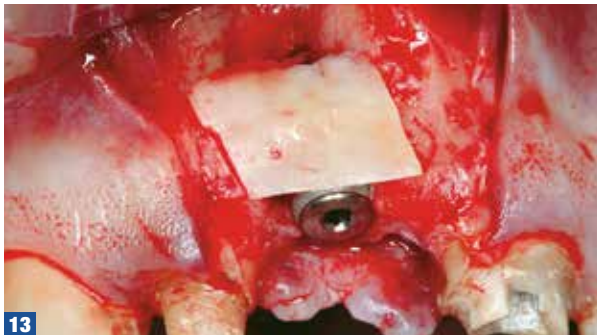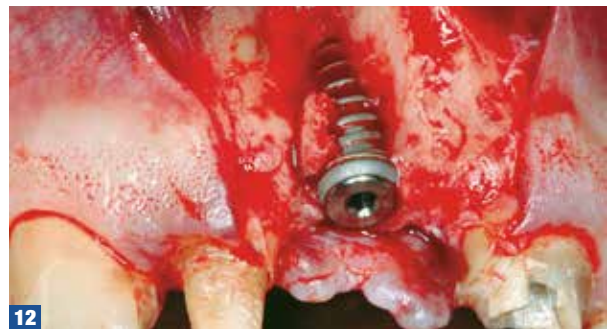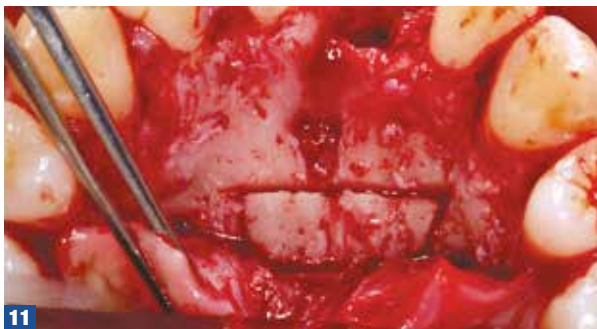Topical anesthetic was applied to the buccal and palatal areas of the anterior maxilla prior to the application of local anaesthesia. Articaine 4% was used to anaesthetize the area. Local infiltration was provided on the buccal and palatal aspects. The palate was anesthetized from the first molar to the first molar on both sides of the palate to ensure profound anaesthesia of the palate during surgery.

A crestal incision was made, followed by two vertical releasing incisions by direct extension. This means the releasing incisions were not one tooth's distance away on either side but rather a direct extension

more. Once the bone plates had been prepared, the implant was placed into the osteotomy (**Fig 12**). The implant is not placed before the bone harvesting, as the harvesting of the plate may lead to the piezo-electric device accidentally contacting the implant. A cover screw is placed following implant placement, and the bone plates were shaped to their final contour to fit the defect (**Fig 13**). Care should be taken to ensure that there is at least 2 mm between the plate and the implant. The plate should not be calculated as part of the 2 mm, as the bone in the plate is nonvital and will resorb over time.

The plate was secured with two 1-mm bone screws (Ustomed) to secure the plates (**Figs 14 and 15**). Care must be taken to ensure the adjacent teeth are not damaged during drilling and placement. The shortest screws should be used to ensure this. The longer the screw, the higher the risk of hitting a vital structure.

The block was then smoothed off with a round diamond bur in a straight handpiece. Do not use a tungsten carbide drill for this as it can vibrate the plate loose. The bone chips were then packed between the plate and the implant (**Fig 16**).



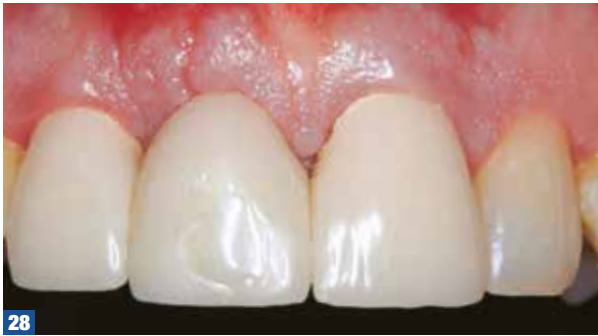11 Palatal view with flap raised and block outlined by the piezoelectric surgical instrument. **12** Implant in position with large buccal dehiscence defect. **13** The split palatal block has been shaped and sized to fit the defect. **14** Bone plate screwed into place, leaving at least 2 mm between the plate and the implant; 1-mm screws are used. **15** Buccal view showing complete coverage of the buccal defect. **16** Occlusal view with the autogenous bone chips packed into the gap created between the plate and the implant.

The final result reflects the attention to detail of each step in the process (**Figs 31 to 34**). The CBCT images (**Figs 35 and 36**) show excellent bone conditions many years after the final restoration.

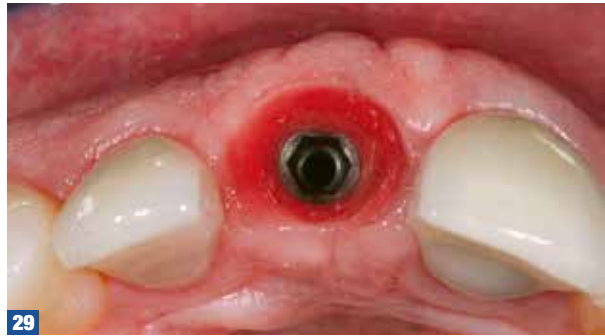The stability of the soft tissue contour is a result of long-term bone stability as well as the augmented soft tissue, which protects the underlying bone.

Indications

This technique is possible with any single anterior tooth that requires GBR as long as the palatal anatomy allows safe bone harvesting. If not, then an alternative site needs to be chosen.

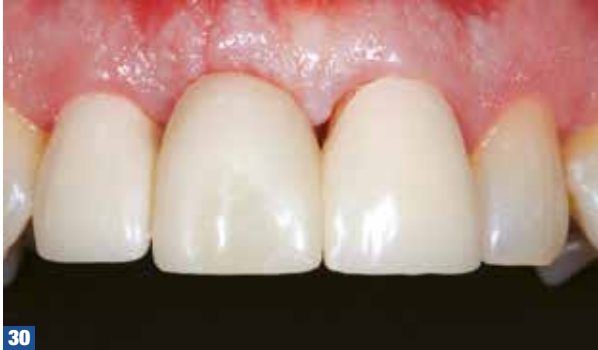

28

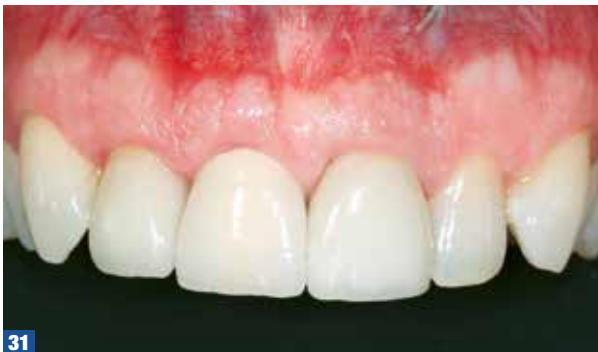

29

28 Individual provisional crowns in place to shape the soft tissue. **29** Occlusal view of the soft tissue development after removal of the provisional crown.

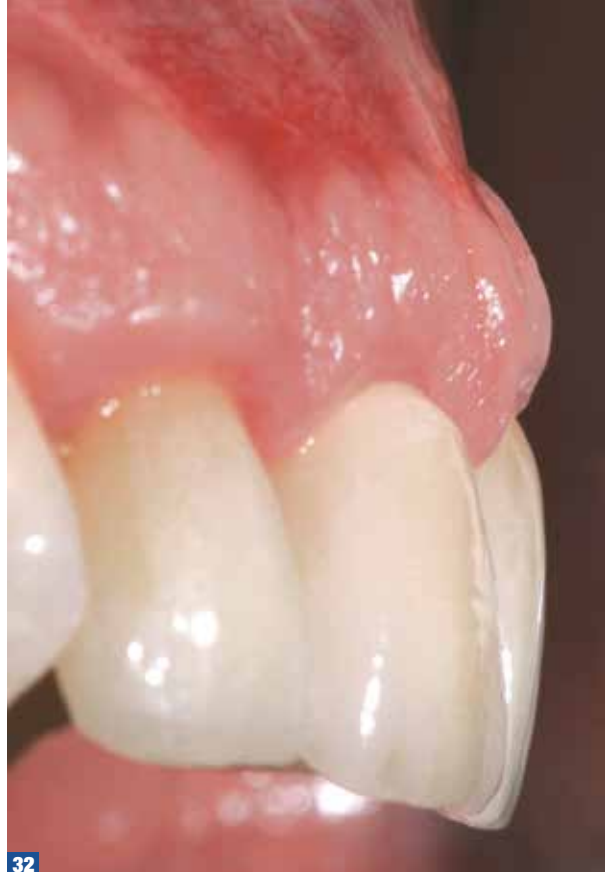

30



31

30 Reshaped provisional crown to correct the soft tissue zenith. **31** Buccal view showing the final crowns 8 years later. **32** Lateral view showing excellent soft-tissue contours and emergence profile.



32

The screws are removed at surgery, and the osteotomies are prepared using osseodensification burs to enhance bone quality further.⁷ The implants are covered and allowed to heal for 3 months before exposure and soft tissue development are carried out. At exposure, connective tissue grafting is performed to further augment the soft tissue profile. Impressions are taken for provisional crowns or partial dentures at the exposure appointment based on

the Digital Smile Design (DSD) protocol developed by Coachman.⁸

The provisional prosthesis is seated no more than 48 hours after the surgery. This allows the soft tissue to be molded by the apical portion of the provisional prosthesis, which creates the ideal soft tissue curves for the final restoration.

The soft tissue is left to heal for about 3 months before the final crowns are placed.



Tips & Tricks

1. When splitting the bone block, make an initial shallow cut to line up all the surfaces. Then the deeper cut can be made, which will guide the thickness of the plates, and a more even split will result.
2. Use nonresorbable monofilament sutures to ensure the stability of flap closure during the entire duration of healing. Removal of the sutures also provides an opportunity to assess healing.



Chapter 12

**Cortical lamina
xenogeneic bone
membrane: indications,
contraindications,
and limitations**

Roberto Rossi and Edoardo Foce



One of the goals of guided bone regeneration (GBR) has been to find a bone substitute that could spare patients from needing an intraoral donor site.

Costa Mendes et al, in a 2016 paper reviewing literature from 1990 to 2015, indicated that intraoral sites became more popular after grafts from the iliac bone crest and calvarium showed various degrees of morbidity. Harvesting from the mandibular symphysis was not very popular, while the mandibular ramus harvest had the lowest complication rate and was better accepted.¹

Nevertheless, the introduction of high-performing biomaterials has challenged the need to resort to autogenous grafts.

In 2016, Rombouts et al studied the angiogenic potential of three different biomaterials of xenogeneic origin: porcine, bovine, and equine.²

Two of the three materials showed significantly enhanced vascular endothelial growth factor (VEGF) secretion by periodontal ligament cells, and an increase in endothelial cell proliferation was observed in cultures with both porcine and equine xenograft conditioned media.

Angiogenesis was stimulated by these two materials, as demonstrated by an increased formation of capillary-like structures.

Another interesting study, conducted by Figueroa et al in 2010, evaluated *in vitro* the physiochemical characterization of biomaterials commonly used in dentistry as bone substitutes, comparing them to human bone.³ The selected materials were available in granules from different biologic origins: bovine, porcine and coralline.

Natural and calcined human bone was used for comparison purposes. Emphasis was placed on

the measurement of various morphostructural properties, such as particle size, porosity, density, and specific surface area.

These properties are crucial to obtaining a full interpretation of the *in vivo* performance.

The porcine-derived biomaterial was the one showing a behavior more similar to human bone. The cortical lamina is produced by the same company, and with the same process used for the bone grafts used in the previous studies, and it is made of collagenated porcine bone in three versions: one curved, one soft, and one rigid.

This chapter evaluates the curved version, while the soft and rigid will be analyzed in chapters 2, 10, 12-15 of this book.

The first clinical evidence of the cortical lamina used in humans was published in a multicenter study by Pagliani et al in 2012.

The study involved 19 patients treated with the cortical lamina for lateral ridge augmentation to improve the performance of sinus elevation and to replace the bone window. The reported success was 91%, as in one case of maxillary sinus augmentation, the procedure resulted in an insufficient bone gain. The histology taken showed bone condensation properties and indicated that the lamina resorbed over time.⁴

In 2013, Wachtel et al published a case series describing the use of the bone lamina technique to perform lateral ridge augmentation. The patients were treated with a combination of the soft lamina and xenogeneic bone particles.

The authors measured the volumetric changes by means of CBCT and took biopsies at the time of implant placement.

The results showed a sufficient bone structure for safe implant placement without the need for any further augmentation. Histologic sections demonstrated new bone formation, and the bone shield completely resorbed.

Their conclusion was that the bone lamina has the biologic and mechanical properties necessary to perform hard tissue augmentation.⁵

In 2016, Rossi et al carried out a study in which 15 implants were placed in the atrophic posterior mandible of 8 patients after their ridge defects were corrected by mean of the cortical lamina.⁶ These patients were treated with a mixture of autogenous bone and blood clot mixed with collagenated porcine xenograft covered with the curved lamina; after healing periods of 6 to 8 months, implants were inserted in the areas where regeneration took

place, and biopsies were taken from the osteotomy sites. All 15 implants achieved osseointegration and showed no modification of their crestal level up to 1 year after loading.

Biopsies showed that areas augmented with the cortical lamina presented new vital bone.

The surgical technique for the application of the cortical lamina, from planning to execution to follow-up, was described step-by-step and in detail by Rossi et al in 2017.⁷

More recently, Rossi et al described the different types of available bone lamina and the precise indications and performances of each individual type.⁸

► **Case report 1: Figs 1 to 41.**

► **Case report 2: Figs 42 to 60.**

CASE REPORT

1

Patient age 58, female

The patient was referred by her general dentist, with a diagnosis of localized severe periodontitis, missing maxillary left premolars, and missing mandibular left molars.

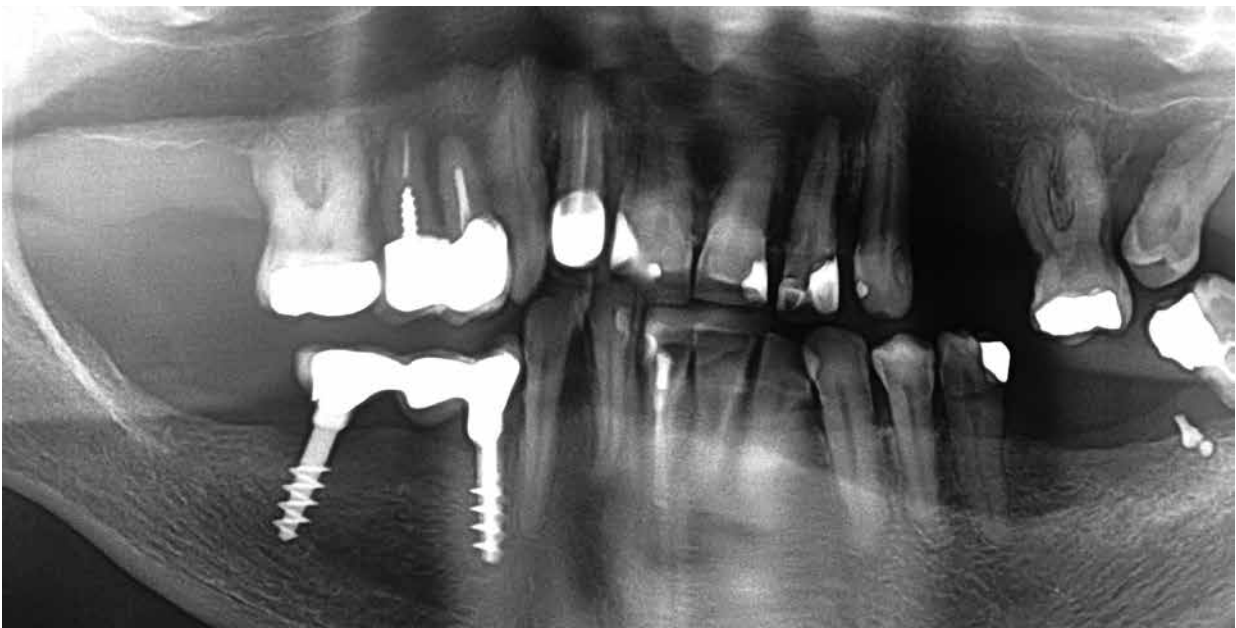
Her maxillary right premolars and first molar, maxillary left second molar, and mandibular left third molar were considered hopeless. The patient presented with a severe horizontal defect in the area of the missing maxillary left premolars, and at the time of the first consultation, a severe vertical defect was anticipated following the removal of the maxillary

right premolars and first molar (**Figs 1 and 2**). Some restorative work was needed as well but would be provided by the referring colleague.

Medical history: No significant findings.

Medications: Pain killers sometimes for headaches.

Esthetic needs: Not particularly interested in esthetics but wanted to improve function.



1 Initial panoramic radiograph.

Proposed surgical treatment plan (after oral hygiene assessment): In the right maxilla, extraction of the premolars and first molar and ridge augmentation with the cortical lamina (curved).

Upon healing, placement of two implants, then restoration with screw-retained restorations. In the left maxilla, insertion of two implants in the sites premolar sites and simultaneous horizontal ridge augmentation. Extraction of the third molar, and placement of two crowns on the premolars. In the left mandible, extraction of the third molar with a single implant in the second molar site and a single crown.

Surgical technique

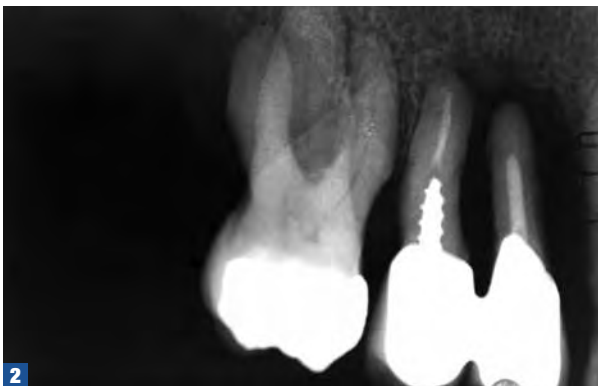
Local anesthesia (articaine with 1:200,000 adrenaline) was administered with palatal infiltration using the anterior middle superior alveolar (AMSA) technique.⁹

Teeth were extracted carefully, and full-thickness flaps (buccal and lingual) were elevated to expose the underlying defect. All granulation tissue was carefully removed, and the defect was measured

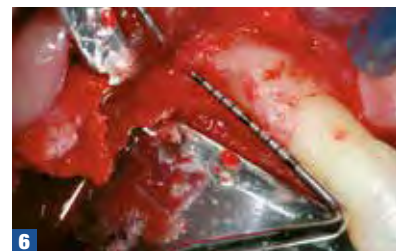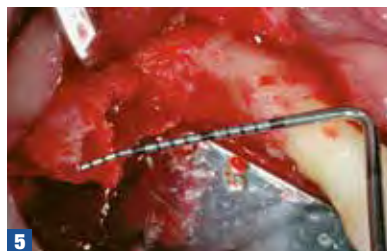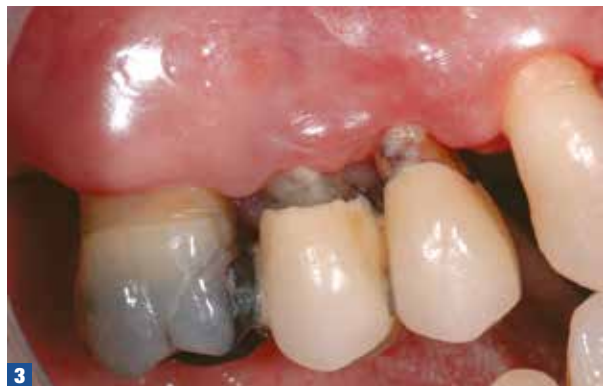(Figs 3 and 4). The defect extended mesiodistally for more than 15 mm, and the apicocoronal dimension had a vertical component of 14 mm (Figs 5 and 6). The buccal and lingual walls were completely destroyed, leaving a completely three-dimensional lesion. In cases like this, the curved lamina represents the easiest solution because of its flexibility, rigidity, and ability to maintain space (Fig 7).

The curved lamina can be bent and adjusted to the local anatomy. The only important precaution is to try to keep it as dry as possible, avoiding soaking it with blood and or saliva until sutures are placed. Since it is made of bone, the lamina should be trimmed with utility scissors instead of surgical scissors or with disks mounted on a handpiece.

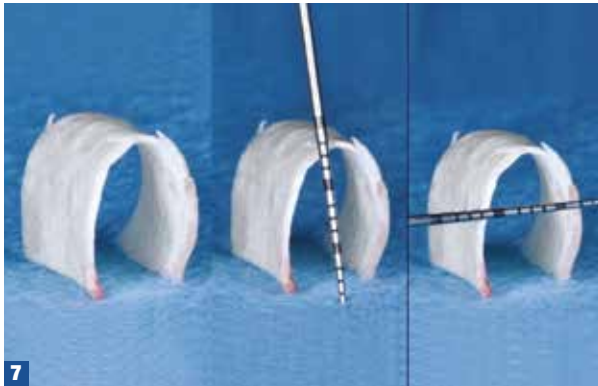
Once the lamina was properly shaped and trimmed to adapt to the local anatomy, it was inserted to create the new ridge. It was attached to the buccal bone with two pins made out of cortical bone by CAD/CAM and reflected buccally (opened like a book) to allow placement and proper packing of the graft (OsteoBiol mp3, Tecnos; Figs 8 to 12).



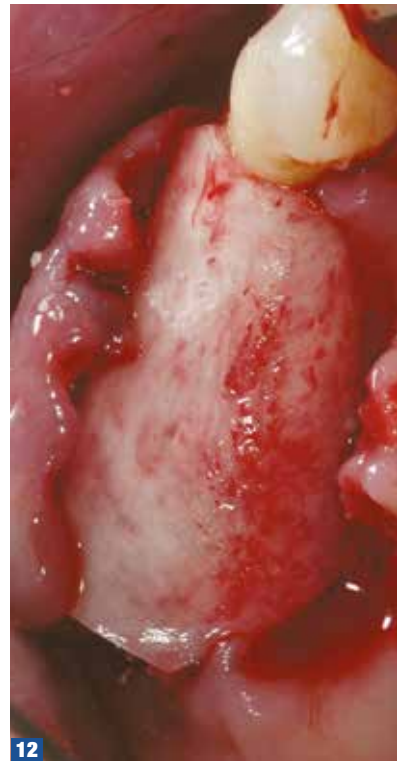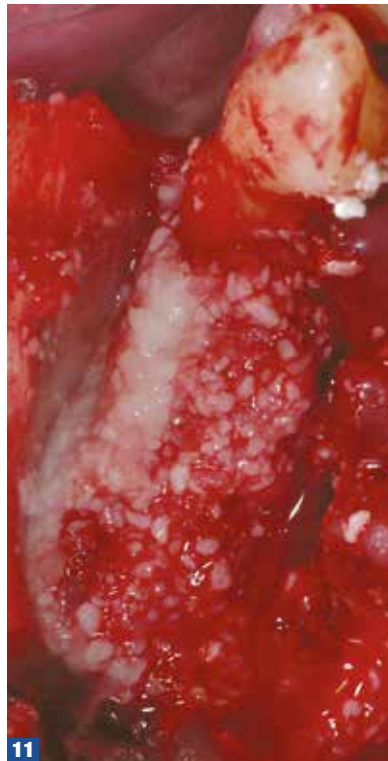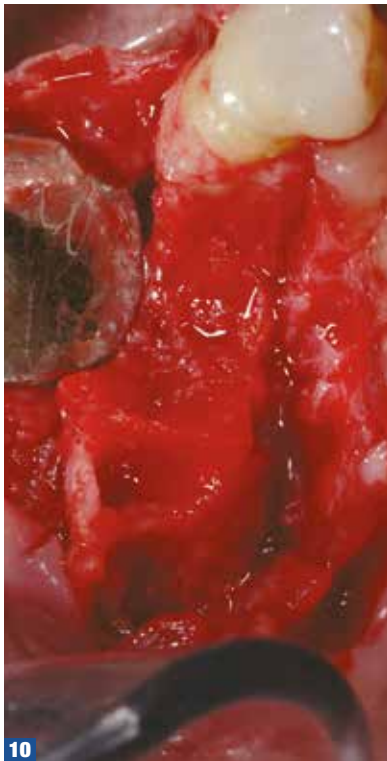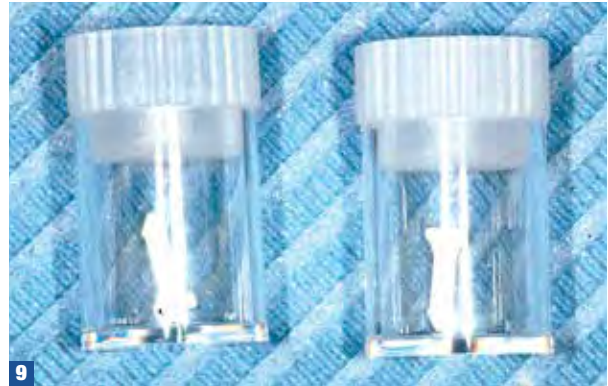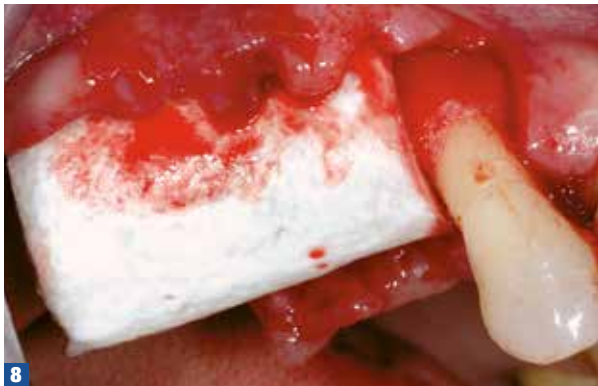2 Detail of the maxillary right quadrant. **3** Buccal view of the maxillary right quadrant before extraction of the premolars and first molar.



4 Buccal view of the defect in the right maxilla following extraction. **5** Measurement of the mesiodistal extension of the defect. **6** Measurement of the apicocoronal extension of the defect.



7 Curved lamina after trimming. 8 Lamina fitted into the defect. 9 Cortical bone pins.



10 Defect before grafting. 11 Graft material (OsteoBiol mp3) mixed with blood clot in place. 12 Lamina in its final position.



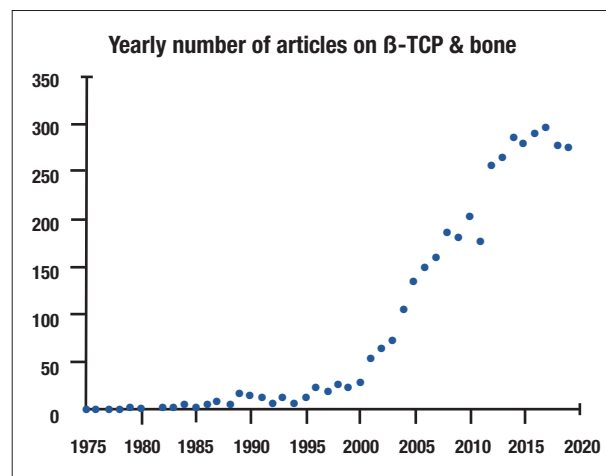
Chapter 19

**Immune modulation
with calcium phosphate
alloplast. Up-regulated,
membrane free
host bone regeneration**

Peter JM Fairbairn

Since the late 1980s, the use of a barrier membrane—either resorbable or nonresorbable—has been advocated for use with particulate graft materials, especially xenografts. This has been termed guided bone regeneration (GBR) by Christer Dahlin and followers, and the membrane was seen as essential to both stabilize the graft material and prevent soft tissue ingrowth. In 2001, the author, amongst others, began working on making particulate grafts stable as well as having an incorporated barrier function, thereby dispensing of the need for a membrane. Since then, the author has completed nearly 7,000 grafts without a membrane and published a 10-year study.¹ This membrane-free protocol was termed true bone regeneration (TBR) by the author in 2008. Synthetic graft materials have been used in bone regeneration since 1892, when Dreesman used calcium sulfate in bone fracture healing. More recently, there have been dramatic improvements in the wide range of synthetic materials, which include: beta-tricalcium phosphate (B-TCP), hydroxyapatite (HA), calcium sulfate (CaS), silicates, and polylactides. These materials now have the most widely published studies on PubMed. The author has looked at, worked with, and researched most of these materials and, along with several colleagues, recently published a broad assessment of this progress in alloplastic materials.² The author's primary interest has been the combination of B-TCP and CaS, and initially the materials were mixed in the clinic by the surgeon. Resorba, a B-TCP material, and Cema (Biocomposites), a CaS material, were mixed at about 70% B-TCP and 30% CaS. In 2003, Biocomposites released a premixed material, Fortoss Vital for dentistry and Genex for orthopedic usage. The ability to use these materials without the need for a barrier membrane was the reason for this combination; the CaS element provides a cell-occlusive barrier, as seen in the research Podaropoulos et al.³ The author then commenced an extensive period of use of Fortoss Vital, perfecting the clinical protocols as well as completing

research on the material.⁴ By 2012, this work led to the development of a new material, EthOss (EthOss Regeneration), which was similar to the previous product but had dramatically improved handling characteristics. In 2013, ceramic expert, Claudio Ranito, worked with the author on the key areas of the B-TCP component: shape, porosity, and size for optimal regenerative performance with EthOss. Why B-TCP? When looking at the ideal properties of a particulate graft material, Yip et al⁵ listed: osteoinductive, osteoconductive, biocompatible, totally replaced by bone, resorbs at the pace of new bone formation, maintains graft stability, satisfactory mechanical properties, and no risk of disease transmission. Only B-TCP fits all of these properties, hence the dramatic rise in research on the material⁶ (**Fig 1**). Why CaS? The addition of CaS makes the material stable, which is essential for bone regeneration and provides a cell-occlusive barrier initially. It is also biocompatible with no host-foreign body cell reaction and has a beneficial effect on soft tissue healing. It has also shown bacteriostatic properties, and at 3 to 4 weeks resorbs, creating space for further neovascular ingrowth for improved angiogenesis.



1 Number of articles by year on β-TCP.

Finally, its dissolution provides nutrients to the healing site.

The published placement protocols and graft time scales¹ allow for soft tissue healing for 3 to 4 weeks to enable soft tissue closure, which occurs prior to the onset of the bone modeling at 5 weeks, as described by many research papers from Shropp, Agaloo, and Tarnow.

Essentially, the protocol is one of preservation and regeneration, with the implant always being placed simultaneous with the grafting. This is due to the up-regulation of the host bone metabolism by the titanium dental implant.

Histology and, more importantly, histomorphometry consistently show more than 50% new host bone and 8% to 12% residual graft material at 12 weeks after grafting through a number of studies by globally renowned histologists, such as Harl Prasad of the University of Minnesota and Chas Mangham of University of Manchester.⁷ Note it is always vital to see the whole core (**Fig 2**). This assessment is essential, as the quality⁸ is more important than the quantity of new bone as it is living tissue that needs to turn over for long-term stability, as described in the research by Chan et al in 2013.⁹

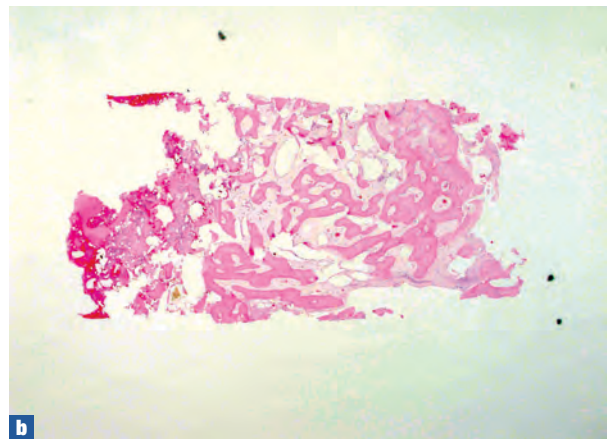
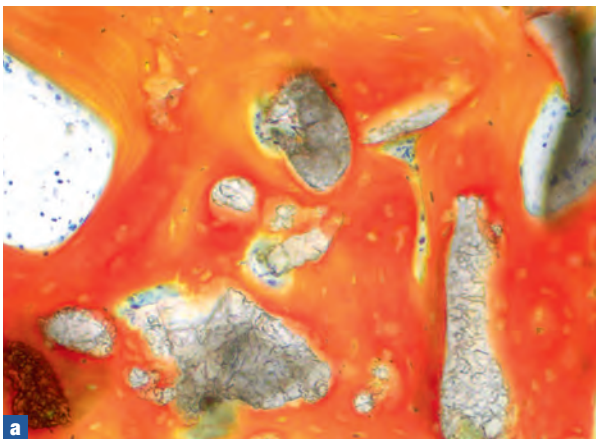
Thus, the full resorption of all the graft material is essential to return the host to healthy bone capable

of supporting an Implant without complications. Another aspect of the importance of healthy host bone around the implant is not merely the bone-to-implant contact, but also the attachment to the keratinized tissue. This is critical in reducing the prospect of peri-implantitis in the future. As Woolf asserted in 1890, the function on the implant will retain the volume of the host hard tissue over the long term. Thus, these materials have ideal characteristics to allow this membrane-free surgery to be stable and cell occlusive.

Recent published research has shown how these CaP materials can modulate the host immune system in osteo-immunology resulting in up-regulated Osteo-Mac polarisation, from M1 (inflammatory) to M2 (regenerative) thus up-regulate the host bone regeneration.¹¹ This has also been noted with EthOss, in immuno-histochemical studies where a dramatic increase in osteoprotegerin, the cytokine for osteoblasts was noted in as little as 2 weeks post grafting.¹²

► **Case report 1: Figs 3 to 26.**

► **Case report 2: Figs 27 to 48.**



2a Histology stained with Von Giesons. **2b** Histology, full core, H and E stain.

CASE REPORT

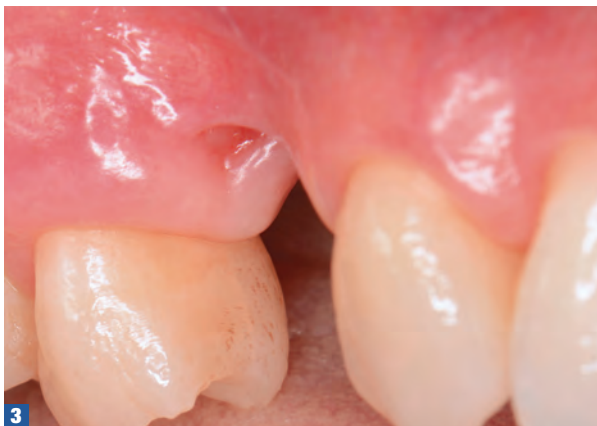1

Patient age 35, female

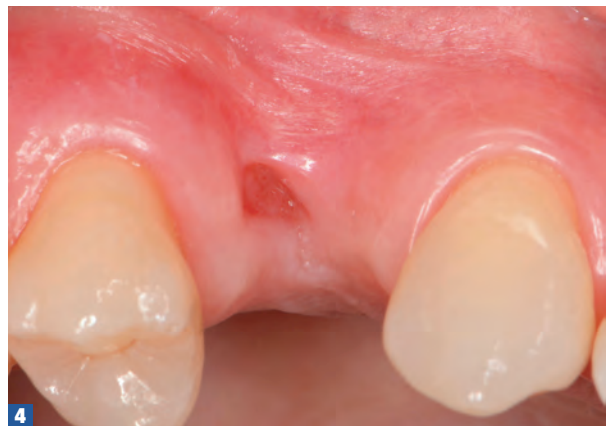Routine protocol for vertical and horizontal bone regeneration.

A 35-year-old female nonsmoking patient was referred 4 weeks after the extraction of her maxillary right first premolar. The resultant loss of both hard and soft tissue can be clearly seen (**Figs 3 and 4**). She was on no medication other than a contraceptive pill and had no underlying medical health issues. A radiograph showed the extent of the hard tissue loss, both buccal and palatal, which also affected the bone on the adjacent second premolar (**Fig 5**). This loss of bone necessitated a move away from the papilla-sparing flap normally used at this site, as

grafting was required to help regenerate the bone on the adjacent second premolar for long-term papilla retention. The patient was then anesthetized with an infiltration of articaine, buccally and palatally, prior to incision. A more extensive flap was raised, revealing the extent of the hard tissue defect as well as the bone loss on the mesial of the second premolar (**Fig 6**). The cleaning and preparation of this root surface must be done with care, as possible progenitor cells for periodontal ligament regeneration may be of great importance.



3



4

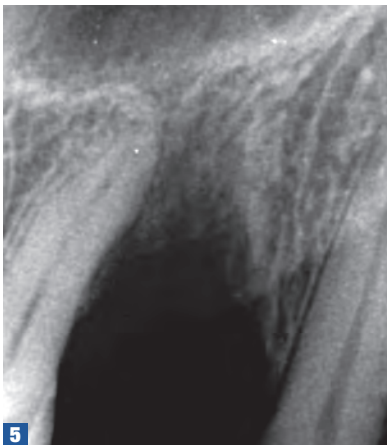
3,4 Preoperative views, 4 weeks after extraction. There is loss of both hard and soft tissue, including keratinized tissue.

The osteotomy was then performed using a 2.0 pilot drill and checked using a radiograph for optimal positioning. Due to the vertical bone loss of both the buccal and palatal plates, half the implant (Anyridge 3.5 × 11.5 mm, MegaGen) would be above the bone level. EthOss was then mixed with saline in a sterile dappen dish to create a wetter mix and placed in the site, with the implant then being screwed into the osteotomy through this mix to the correct level (**Fig 7**). The implant level could be visualized to be in the correct position to end up 1 mm subcrestal when the host bone was regenerated (**Fig 8**).

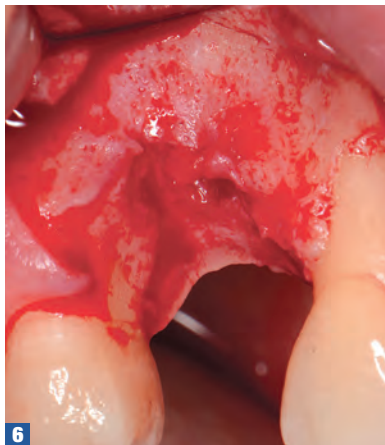Then the other half of the EthOss was added (using a 0.5-mL syringe) to the previously placed material, and with a minimum of saline added, a “drier” mix

was made and applied over the site and then set using sterile gauze to stabilize the material (**Figs 9 to 11**). The key is to not place too much graft material, as this is a regenerative procedure that relies on the host periosteum, which must be kept close to the regenerative site. Less graft material makes it easier to obtain flap closure without tension. This closure was done by suturing with polytetrafluoroethylene (PTFE) sutures (Coreflon); there was a small opening on the palatal aspect, which would heal by secondary intention within a few days (**Fig 13**).

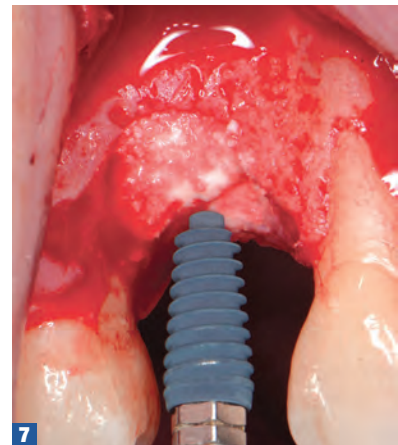
This reduced flap without extensive release has two primary benefits: it is more stable due to less release, which improves host bone regeneration, and there is movement of keratinized tissue buccally,



5

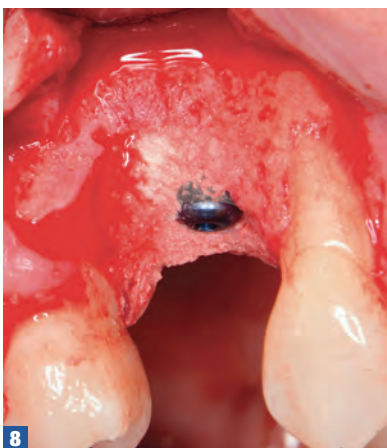

6

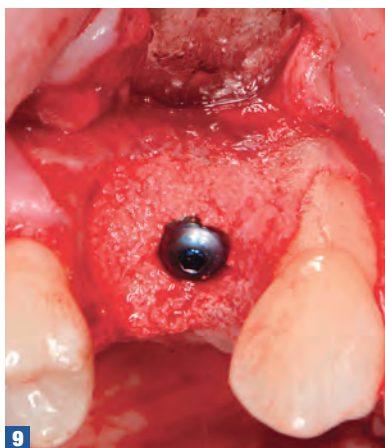


7

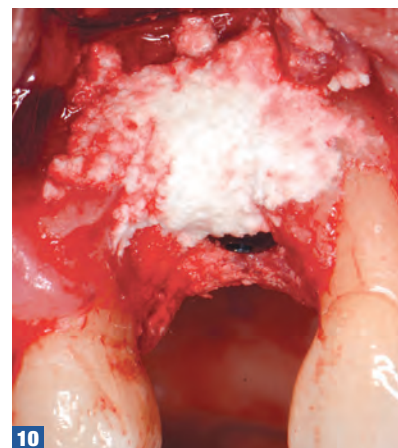
5 Radiograph showing hard tissue loss. **6** Flap raised to show bone loss. **7** Placement of EthOss graft and implant.



8



9



10

8,9 Implant placed to the correct level. **10** Drier EthOss added, taking care not to place too much volume of graft.